

Urticarial papules and plaques on the trunk

A 65-year-old female was being treated with cyclophosphamide for follicular dendritic cell tumor of the cervical lymph nodes. She presented to us with erythematous painful eruption on the extremities and trunk that started approximately one week after starting the chemotherapy. She had been treated with chlorpheniramine followed by a course of prednisolone 30 mg OD for one week. This caused resolution of the lesions, but they recurred after the corticosteroids were stopped. The patient was otherwise fit and well with no other symptoms. She was on no other medication. Examination revealed numerous tender, erythematous and edematous papules and plaques on her trunk and proximal parts of extremities [Figure 1a and b]. Her palms and soles were spared.

Complete blood count, renal and liver function tests, electrolytes and autoantibody screen were normal with the exception of an elevated neutrophil count ($12.10 \times 10^9/L$). Skin biopsy taken from one of the lesions showed a polymorphous inflammatory reaction within and around some eccrine sweat ducts, consisting of many neutrophils and a few lymphocytes without red blood cells extravasation [Figure 2].

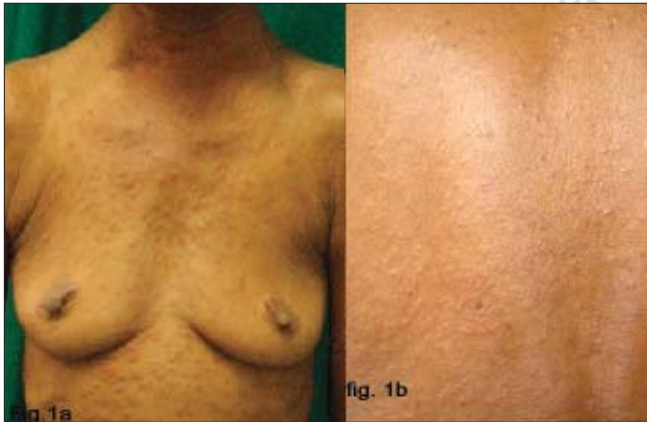

Figure 1: Erythematous plaques on the trunk and upper extremities of the patient after cyclophosphamide

Special stains with Perls and Rouge Congo were negative. Acid-fast bacilli, periodic acid-Schiff and Gomori methenamine silver stains and a tissue culture were all negative for infection. Cyclophosphamide was stopped and over the course of the next week, the eruption gradually resolved without any other intervention.

WHAT IS YOUR DIAGNOSIS?

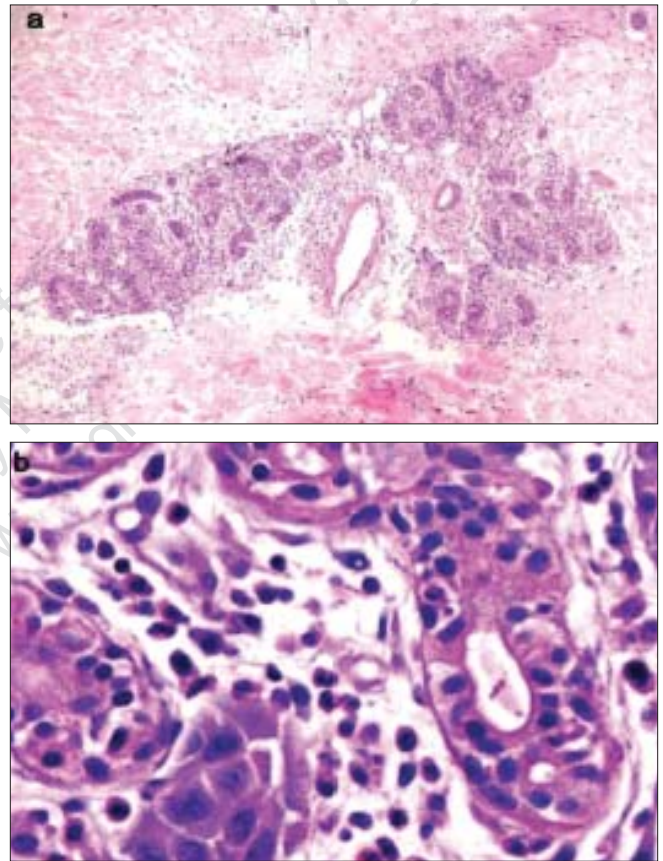


Figure 2: Histopathology showing a neutrophilic infiltrate around the sweat glands and degeneration of eccrine glands (H and E stain (a) 100x; (b) 1000x)

How to cite this article: Narang T, Kanwar AJ, Dogra S, Radotra BD. Urticarial papules and plaques on the trunk. *Indian J Dermatol Venereol Leprol* 2007;73:63-4.

Received: July, 2005. **Accepted:** July, 2006. **Source of Support:** Nil. **Conflict of Interest:** None declared

Diagnosis: Neutrophilic eccrine hidradenitis

DISCUSSION

Neutrophilic eccrine hidradenitis (NEH) is a rare condition with a highly variable clinical presentation. Lesions range from erythematous papules to indurated nodules and plaques of varying sizes. There may be associated pigmentary or purpuric change. The lesions are usually asymptomatic, but may be pruritic or tender. Common sites of involvement are the trunk and upper limbs. Fever is often associated.^[1,2] The diversity of clinical presentations can mimic a range of other conditions including Sweets syndrome, urticarial vasculitis, disseminated bacterial/fungal infection and leukemic infiltrates.^[3]

The characteristic histological features of NEH generally allow the diagnosis to be made. These are vacuolar degenerative changes and necrosis within the secretory cells of the eccrine sweat glands, with a surrounding dense, predominantly neutrophilic infiltrate in the deep dermis. The neutrophilic infiltrate may be mild in patients with a neutropenia. Diffuse dermal edema with perivascular infiltrate consisting of lymphocytes, neutrophils, macrophages and eosinophils may also be seen. Features like apocrine involvement and epidermal lichenoid tissue reaction can also be seen.^[3]

The etiology of NEH is unclear; however, there are two theories regarding its pathogenesis. The first suggests that NEH belongs to the spectrum of neutrophilic dermatoses, with primary involvement of the eccrine glands. The other theory postulates that the infiltrate in NEH is secondary to drug-induced eccrine gland changes. Several studies have suggested that NEH belongs to the spectrum of drug-induced eccrine gland changes that include syringosquamous metaplasia and eccrine necrosis. There are several reports of chemotherapy-related eruptions in which histological examination showed isolated necrosis or syringometaplasia of the eccrine coils without neutrophilic infiltration.^[4,5]

Different kinds of agents have been implicated as etiologies. Cytarabine and bleomycin are the two most often associated with NEH, but the list also includes cyclophosphamide, topotecan, methotrexate, granulocyte colony stimulating factor (G-CSF), lomustine, doxorubicin, bleomycin, 5-fluorouracil, vinblastine, VAPA-10 and dacarbazine.^[3,4] In these cases, NEH has been considered to represent focal toxicity to the eccrine unit, lying within the spectrum of drug-induced eccrine gland changes.^[5] Microorganisms, such as HIV, hepatitis C virus, *Serratia*, *Enterobacter*, *Staphylococci* and *Nocardia* have

also been implicated. Other causes include malignancy alone, reverse transcriptase inhibitors and rheumatologic disease (Behcet's disease).^[6] The diversity of the presentations suggests that NEH represents a cutaneous reaction pattern to a broad spectrum of clinical conditions.^[3]

The mainstay of treatment is to withdraw any implicated drug. This is usually sufficient because NEH tends to resolve spontaneously within a few weeks. Due to the sporadic nature of the disease, it has yet to be determined whether prophylactic nonsteroidal anti-inflammatory drugs, corticosteroids or dapsone are helpful in preventing recurrences with subsequent courses of chemotherapy.

Recognition of NEH is important in order to exclude other neutrophilic dermatoses associated with malignancies, such as sepsis and acute febrile neutrophilic dermatoses, which may appear clinically similar. Rapid diagnosis may avert unnecessary changes in therapy to treat conditions which clinically mimic NEH.

**Tarun Narang, Amrinder Jit Kanwar,
Sunil Dogra, Bishan Dass Radotra***

Departments of Dermatology, Venereology and Leprology and
*Pathology, Postgraduate Institute of Medical Education and
Research, Chandigarh, India.

**Address for Correspondence: Dr. A. J. Kanwar,
Department of Dermatology, Venereology and Leprology,
Postgraduate Institute of Medical Education and Research,
Chandigarh - 160 012, India. E-mail: kanwaraj@hotmail.com**

REFERENCES

- Harrist TJ, Fine JD, Berman RS, Murphy GF, Mihm MC Jr. Neutrophilic eccrine hidradenitis. A distinctive type of neutrophilic dermatosis associated with myelogenous leukemia and chemotherapy. *Arch Dermatol* 1982;118:263-6.
- Susser WS, Whitaker-Worth DL, Grant-Kels JM. Mucocutaneous reactions to chemotherapy. *J Am Acad Dermatol* 1999;40:367-98, 399-400.
- Bachmeyer C, Aractingi S. Neutrophilic eccrine hidradenitis. *Clin Dermatol* 2000;18:319-30.
- Greenbaum BH, Heymann WR, Reid CS, Travis SF, Donaldson MH. Chemotherapy-associated eccrine hidradenitis, neutrophilic eccrine hidradenitis reevaluated: The role of neutrophilic infiltration. *Med Pediatr Oncol* 1988;16:351-5.
- Hurt MA, Halvorson RD, Petr FC Jr, Cooper JT Jr, Friedman DJ. Eccrine squamous syringometaplasia: A cutaneous sweat gland reaction in the histological spectrum of chemotherapy-associated eccrine hidradenitis and neutrophilic eccrine hidradenitis. *Arch Dermatol* 1990;126:73-7.
- Bilic M, Mutasim DF. Neutrophilic eccrine hidradenitis in a patient with Behcet's disease. *Cutis* 2001;68:107-11.