

Fractional carbon dioxide laser treatment for refractory exfoliative cheilitis

Dear Editor,

Exfoliative cheilitis, an inflammatory condition of the lips, is characterised by symptoms such as desquamation, crusting, dryness, chapping, erythema and swelling, often accompanied by pruritus or pain. Multiple treatments have been tried including emollients, topical steroids and calcineurin inhibitors but long-term remission remains a challenge.¹ Here, we report the successful treatment of two patients with refractory exfoliative cheilitis using fractional carbon dioxide (CO₂) laser, who continued to have good symptom resolution even on long-term follow-up.

Patient 1 was a 24-year-old woman who presented with complaints of painful, flaky, chapped lips for over a decade. Patient 2 was a 34-year-old woman who had experienced recurrent redness, dryness, flaking and crusting on her lips and perioral skin for more than a year. Both denied aggravation with sun exposure or seasonal variations and had no systemic comorbidities. Patient 1 admitted to licking and biting her lips but a similar history was not forthcoming for the second patient. Prior treatments with topical corticosteroids and tacrolimus were ineffective.

Upon initial examination, both patients exhibited erythema, desquamation and crusting of both upper and lower lips [Figure 1a and 1b]. Dermoscopy revealed punctate and short line vessels with epidermal rupture and bleeding [Figure 1c and 1d]. Reflectance confocal microscopy (RCM) showed dilated capillaries in dermal papillae, with uneven perivascular inflammatory cell infiltration [Figure 1e and 1f]. Transepidermal water loss (TEWL) was elevated, and skin capacitance value were lowered (Patient 1: 83.9 g/m²·h and 38 AU, respectively, Patient 2: 90.4 g/m²·h and 23.5 AU, respectively). Dermatology Life Quality Index (DLQI) scores indicated a significant impact on quality of life with a score of 10 and 12 respectively.

A diagnosis of refractory exfoliative cheilitis was made. Both patients underwent three sessions of fractional CO₂ laser treatment (3 ms pulse width, 9 mm spot size, 31% coverage density, one time overlap, 36 mJ energy) at one-month intervals. Response was assessed at each treatment session and at 3 months post-treatment follow-up after the final session. There was visible improvement in desquamation, chapping and erythema with treatment [Figure 2a and 2b]. Dermoscopy showed lightening of the colour of the lesions

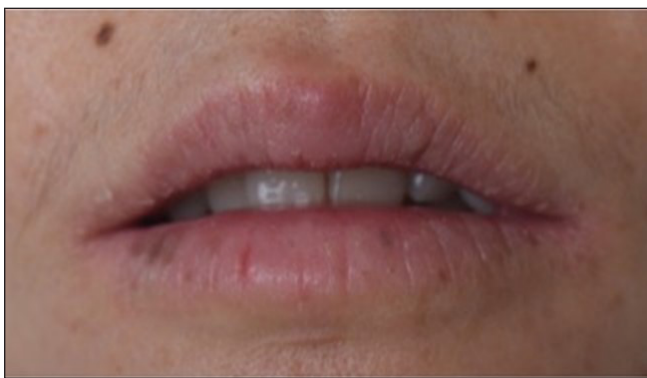

Figure 1a: Clinical photograph of patient 1 prior to treatment.

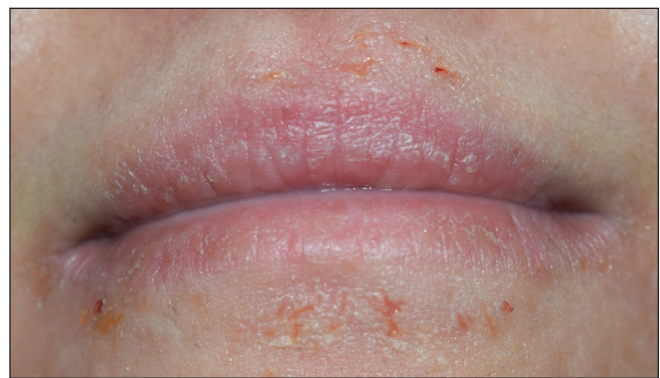

Figure 1b: Pre-treatment clinical photograph of patient 2.

How to cite this article: Yu N, Zhou X, Wang X, Zhang M. Fractional carbon dioxide laser treatment for refractory exfoliative cheilitis. *Indian J Dermatol Venereol Leprol*. doi: 10.25259/IJDVL_894_2024

Received: June, 2024 **Accepted:** October, 2024 **Epub Ahead of Print:** January, 2025

DOI: 10.25259/IJDVL_894_2024

This is an open-access article distributed under the terms of the Creative Commons Attribution-Non Commercial-Share Alike 4.0 License, which allows others to remix, transform, and build upon the work non-commercially, as long as the author is credited and the new creations are licensed under the identical terms.

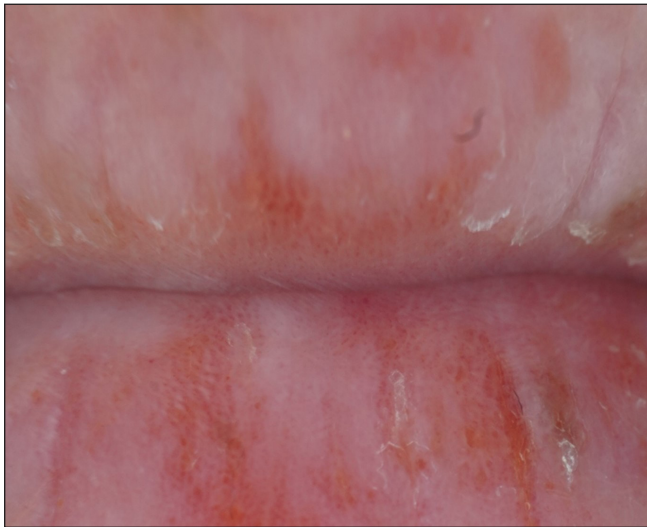

Figure 1c: Dermoscopic finding before the initial treatment of patient 1 (Polarised mode, 20x).

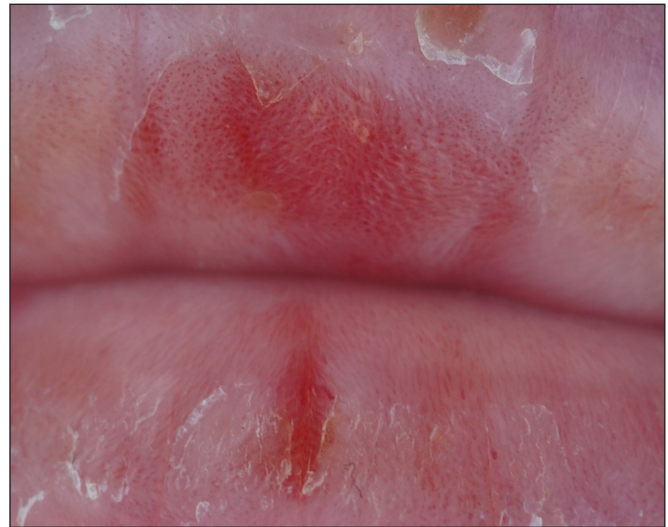


Figure 1d: Dermoscopic finding before the initial treatment of patient 2 (Polarised mode, 20x).

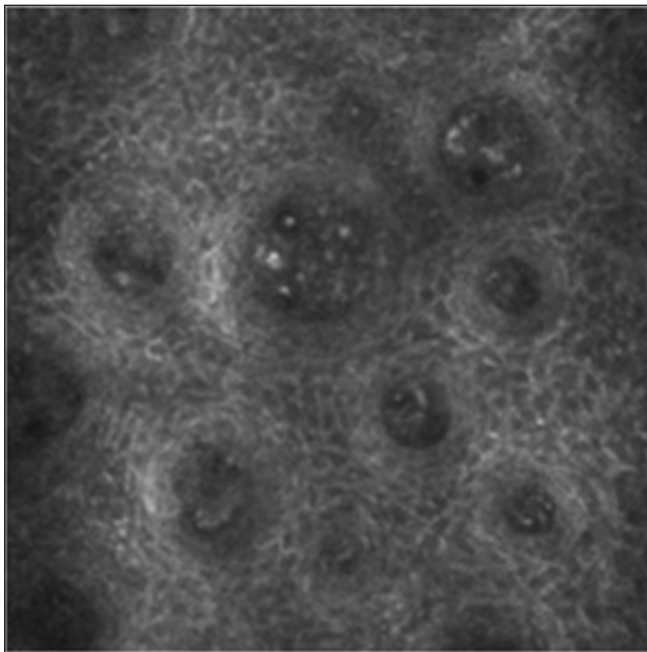


Figure 1e: Reflectance confocal microscopy (RCM) image prior to the first treatment session of patient 1.

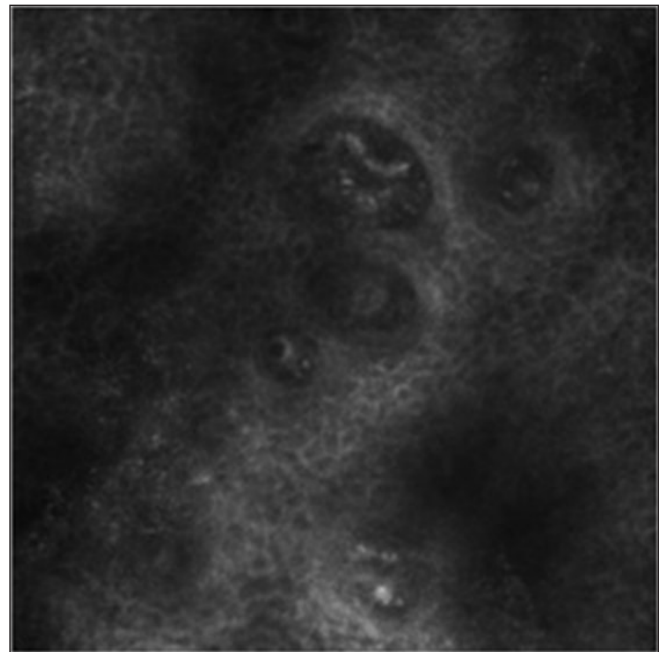


Figure 1f: Reflectance confocal microscopy (RCM) image was captured prior to the first therapeutic intervention of patient 2.

and reduction in the number of vessels [Figure 2c and 2d]. Dilated capillaries and perivascular inflammatory cell infiltrate decreased in RCM as treatment advanced [Figure 2e and 2f] and TEWL and skin capacitance showed gradual improvement [Figure 3a-d]. DLQI score reduced to 2 for both the patients, indicating an improved quality of life. No pain, scarring or recurrence was observed during treatment and follow-up.

Dermoscopy and RCM enhance diagnostic accuracy in dermatology but have not been explored in exfoliative cheilitis until now. This study employed dermoscopy to identify punctate and linear blood vessels, which diminished in number and lightened in background colour with treatment.

RCM findings included pronounced capillary dilation and congestion in the superficial dermis accompanied by increased inflammatory cell infiltration and a significant reduction in these parameters was observed as treatment progressed. These preliminary results require validation through larger studies.

The treatment of exfoliative cheilitis is challenging, with conventional therapies, including topical treatments, providing limited relief. When these fail, alternative treatments such as excimer laser² and CO₂ laser pinhole method³ have been reported to be effective. Our case, resistant to conventional therapy, showed significant improvement with fractional CO₂ laser therapy, representing a novel application in this context.

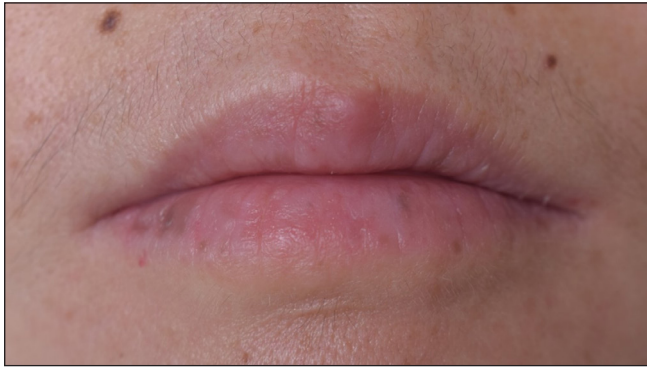

Figure 2a: Clinical photograph at the three months after the last treatment of patient 1.

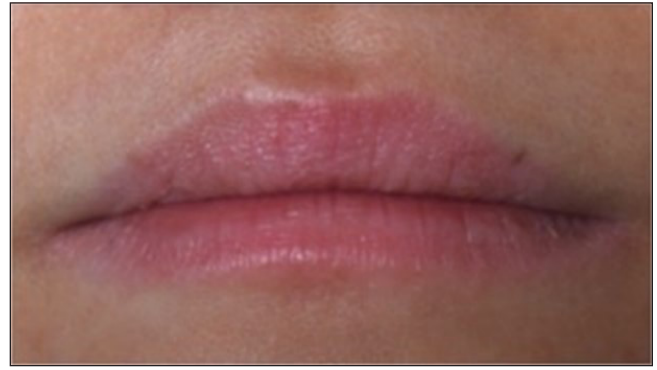

Figure 2b: Clinical appearance at the three months after the last treatment of patient 2.

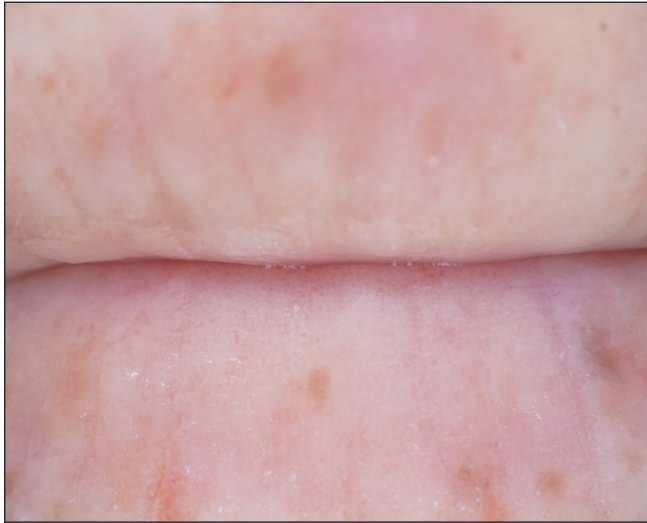

Figure 2c: Dermoscopic finding at the three months after the final session of patient 1 (Polarised mode, 20x).

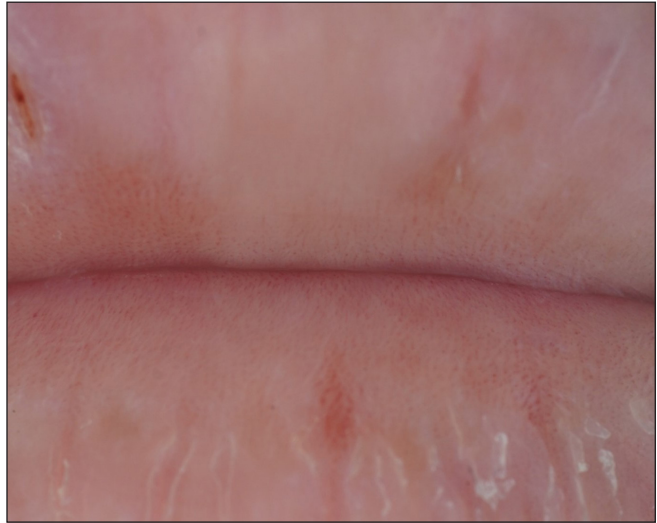

Figure 2d: Dermoscopic finding at the three months after the final session of patient 2 (Polarised mode, 20x).

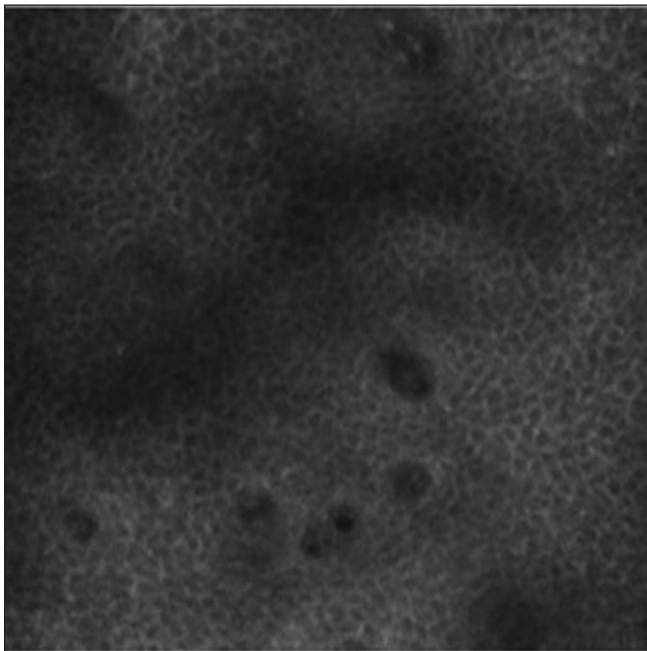


Figure 2e: RCM image at the three-month post the final treatment session of patient 1.

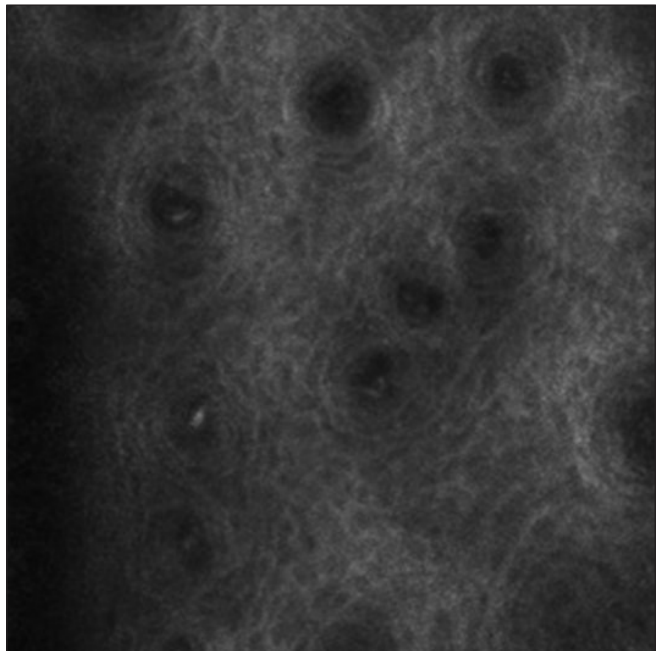


Figure 2f: RCM image was captured three months after the final treatment session of patient 2.

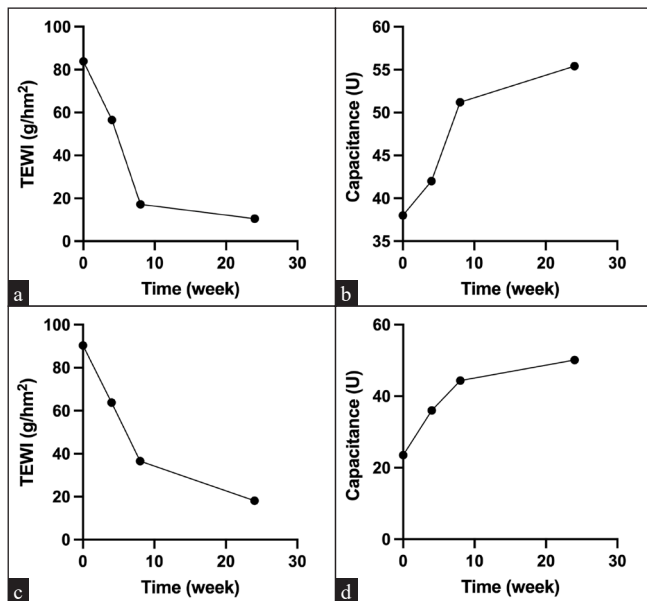


Figure 3: Patient 1- Change in (a) TEWI and (b) Capacitance, Patient 2- Change in (c) TEWI and (d) Capacitance, following treatment.

Fractional CO₂ lasers operate at 10,600 nm, targeting water to create microthermal zones that stimulate collagen formation and accelerate healing. We speculate that the mechanism of action of fractional CO₂ lasers in the management of exfoliative cheilitis involves several processes. First, the laser can repair the skin barrier and reduce TEWL through re-epithelialisation and skin regeneration.⁴ Guo *et al.* identified the upregulation of several skin barrier pathways following fractional CO₂ laser treatment, as discovered through transcriptome sequencing technology.⁵ Second, fractional CO₂ laser therapy achieves tissue ablation along its energy path. The high temperature achieved by the laser energy can cause the blood within the vessels to boil and vaporise, leading to vessel wall rupture and coagulation, thereby reducing erythema.⁶ Additionally, the treatment remodels the collagen architecture, reorienting the surrounding vasculature into both perpendicular and parallel planes, which further ameliorates vascularity.⁷ Last, these mechanisms may lead to a reduction in inflammatory cell infiltration, thereby further improving the condition. Further research with larger cohorts

and histological corroboration is essential to substantiate these hypotheses.

Declaration of patient consent: The authors certify that they have obtained all appropriate patient consent.

Financial support and sponsorship: This work was supported by the National Natural Science Foundation of China (82103761).

Conflicts of interest: There are no conflicts of interest.

Use of artificial intelligence (AI)-assisted technology for manuscript preparation: The authors confirm that there was no use of AI-assisted technology for assisting in the writing or editing of the manuscript and no images were manipulated using AI.

*Nanlan Yu¹, Xiaofang Zhou¹, Xin Wang¹,
Mingwang Zhang¹*

¹Department of Dermatology,
Southwest Hospital, Army Medical University, Chongqing, China.

Corresponding authors:

Dr. Xin Wang and Dr. Mingwang Zhang,
Department of Dermatology,

Southwest Hospital, Army Medical University, Chongqing, China.

wx18602340679@163.com and

mingwangzhang2@163.com

References

- Almazrooa SA, Woo SB, Mawardi H, Treister N. Characterization and management of exfoliative cheilitis: A single-center experience. *Oral Surg Oral Med Oral Pathol Oral Radiol* 2013;116:e485–9.
- Bhatia BK, Bahr BA, Murase JE. Excimer laser therapy and narrowband ultraviolet B therapy for exfoliative cheilitis. *Int J Womens Dermatol* 2015;1:95–8.
- Park CS, Park JH, Lee J, Byun HJ, Lim Y, Lee JH, *et al.* Chronic exfoliative cheilitis successfully treated by pinhole method using CO₂ laser. *Ann Dermatol* 2019;31:361–3.
- Mu YZ, Jiang L, Yang H. The efficacy of fractional ablative carbon dioxide laser combined with other therapies in acne scars. *Dermatol Ther* 2019;32:e13084.
- Guo H, Zhang X, Li H, Fu C, Jiang L, Hu Y, *et al.* Dynamic panoramic presentation of skin function after fractional CO₂ laser treatment. *iScience* 2023;26:107559.
- Zhang T. Extended application of fractional carbon dioxide laser in the treatment of port wine stain birthmarks with hypertrophy: A case report. *Photobiomodul Photomed Laser Surg* 2023;41:189–92.
- Ozog DM, Liu A, Chaffins ML, Ormsby AH, Fincher EF, Chipps LK, *et al.* Evaluation of clinical results, histological architecture, and collagen expression following treatment of mature burn scars with a fractional carbon dioxide laser. *JAMA Dermatol* 2013;149:50–7.