

Mycetoma in north-western Yemen: Clinico-epidemiological and histopathological study

Mishri Lal Khatri, Sultan Ahmed Saif Al Kubati¹, Ismail Ahmed Gaffer², Shaban M. Abdel Majeed³

Departments of Dermatology, ¹Pathology, ²Orthopaedics, ³General Surgery, Saudi Hospital, Hajjah, Yemen

Abstract

Background: Mycetoma is widespread in Yemen; however, there are only a few documented reports on the entity from this geographical area.

Methods: A prospective study of 184 cases of mycetoma (male 145 and female 39) from different regions of north-western Yemen was conducted between July 2000 and May 2014. Clinical profile was recorded in a standardized protocol. The diagnosis was based on clinical features, X-ray studies, examination of grains, and histopathology.

Results: Eumycetoma was diagnosed in 129, caused by *Madurella mycetomatis* in 124, *Leptosphaeria senegalensis* in one and pale grain fungus in four, whereas actinomycetoma occurred in 55, caused by *Streptomyces somaliensis* in 29, *Actinomadura madurai* in nine, *Actinomadura pelletieri* in one, and *Nocardia* in sixteen. Eumycetoma cases were treated with prolonged course of antifungal drugs, mostly ketoconazole, with itraconazole being used in four patients, along with excision or debulking. Results were better when antifungal drugs were given two to three months before surgery and in those who received itraconazole. Actinomycetoma cases were initially treated with co-trimoxazole monotherapy; later streptomycin was added in 30 cases. Six patients who did not show adequate improvement and two others from the start were treated with modified Welsh regimen and with good results.

Limitations: Identification of different causative agents was done by histopathology and could not be reconfirmed by culture.

Conclusion: Mycetoma is widespread in north-western Yemen with a higher incidence of eumycetoma and a majority of the cases were caused by *Madurella mycetomatis*. Modified Welsh regimen in actinomycetoma and itraconazole with excision in eumycetoma showed the best results.

Key words: Actinomycetoma, eumycetoma, mycetoma, north-western Yemen

Plain Language Summary

Mycetoma is a chronic subcutaneous infection caused by different fungal (eumycetoma) and bacterial agents (actinomycetoma) characterized by formation of swelling with sinuses, discharging different coloured granules. The disease is common in India and other tropical and subtropical countries. The present study was performed at Saudi Hospital at Hajjah, in the north-west Yemen between July 2000 and May 2014 to evaluate the epidemiologic aspect along with identification of causative organism by histopathology and assess the outcome of different treatment modalities. The total number of patients was 184. Eumycetoma was diagnosed in 129 and actinomycetoma in 55. The most common causative agent was *Madurella mycetomatis*. Eumycetoma was treated with prolonged course of antifungal drugs, mostly ketoconazole and itraconazole and, in few, with excision or debulking. Actinomycetoma was first treated with co-trimoxazole monotherapy; later, streptomycin was added in some cases. Few patients who did not improve well were treated with modified Welsh regimen and showed the best results. Mycetoma is widespread in north-west of Yemen with higher incidence of eumycetoma caused by *Madurella mycetomatis*. Maximum number of cases were from the Al-Hudaydah governorate.

How to cite this article: Khatri ML, Al Kubati SA, Gaffer IA, Majeed SM. Mycetoma in north-western Yemen: Clinico-epidemiological and histopathological study. Indian J Dermatol Venereol Leprol 2022;88:615-22.

Corresponding author: Dr. M. L. Khatri, Senior Consultant, Dermatology & Dermatopathology, 16 B First Polo, Jodhpur 342006, India. mishrik1@yahoo.co.in

Received: May, 2021 **Accepted:** October, 2021 **Epub Ahead of Print:** March, 2022 **Published:** August, 2022

DOI: 10.25259/IJDVL_500_2021 **PMID:** 35389029

This is an open-access article distributed under the terms of the Creative Commons Attribution-Non Commercial-Share Alike 4.0 License, which allows others to remix, transform, and build upon the work non-commercially, as long as the author is credited and the new creations are licensed under the identical terms.

Introduction

Mycetoma is a chronic granulomatous subcutaneous infection, caused by a variety of fungal (eumycetoma) and bacterial (actinomycetoma) agents, characterized by formation of localized lesions with multiple sinuses, discharging grains which may be yellow, white, red, brown, or black depending on the causative agent. It is endemic in India, Sudan, Senegal, Somalia, Yemen, Mexico, Venezuela, and other tropical and subtropical countries between latitude 15° S and 30° N all around the globe.¹⁻³ Although, there have been a few previous reports,^{4,9} the extent of mycetoma in Yemen is not fully documented. This was a prospective study of 184 mycetoma cases seen between July 2000 and May 2014 at dermatology clinic of Saudi Hospital at Hajjah, in north-west of Republic of Yemen. For planning effective treatment of mycetoma, it is essential to investigate for causative agents, which can be done by histopathology and/or culture. A clinico-epidemiological, histopathological and therapeutic study of these cases is presented. The study was approved by the institutional ethics committee.

Material and Methods

A prospective study of 184 cases of mycetoma (male 145 and female 39) was conducted at the dermatology clinic of Saudi Hospital at

Table 1: Location of the lesions

Locations	Eumycetoma (129 patients)	Actinomycetoma (55 patients)	Total (184)
Foot	103	39	142
Ankle	11	4	15
Leg	6	2	8
Knee	6	3	9
Thighs	1		1
Gluteal region	10		10
Perineum	2		2
Hand	5	4	9
Scalp	1	1	2
Chest	3		3
Abdomen	2		2
Axilla	1		1
Back	1		1
Total sites	148	57	205

More than one sites in 18 patients

Hajjah, in the north-west of Republic of Yemen between July 2000 and May 2014. Details of history, physical findings, laboratory data, treatment and follow-up were recorded in a standardized protocol, with special emphasis on geographic history. Routine investigations including complete blood counts, blood sugars, liver function, renal function and glucose-6-phosphohate dehydrogenase tests were performed in all the patients. X-ray studies were also performed in all cases. Grains were examined using potassium hydroxide (KOH) preparation. Histopathological studies were also performed in all the cases. Six mm punch biopsy was taken from the representative site of the lesion (around the path of the sinus) in most of the cases and excision biopsy in others. The tissue sections were stained with haematoxylin & eosin stain routinely. The diagnosis was based on clinical features, X-ray studies, examination of grains and histopathology findings.

Results

All patients were Yemeni nationals, residents of different governorates, as shown in Figure 1. Age of the patients

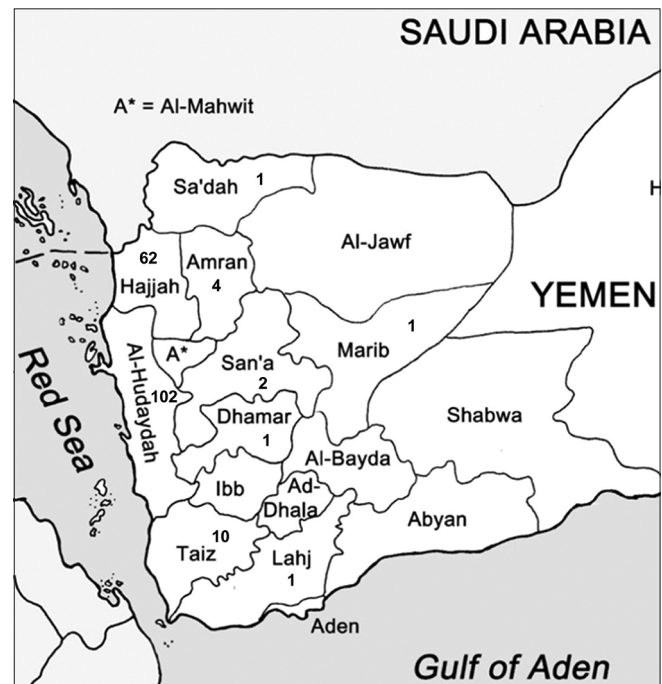

Figure 1: Map showing distribution of mycetoma in north-west Yemen

Table 2: Geographical distribution of causative agents of mycetoma in Yemen

Governorates	<i>Madurella mycetomatis</i>	<i>Leptosphaeria senegalensis</i>	Pale gr. fungus	<i>Streptomyces somaliensis</i>	<i>Actinomyces madurae</i>	<i>A. pelletieri</i>	<i>Nocardia</i>	Total
Al Hudaydah	78		1	19	3	1		102
Hajjah	40		1	4	4		13	62
Kohlhan Affar	2			2				4
Taiz	4	1	1	1	1		2	10
Sadah			1					1
Damar				1				1
Lahaj				1				1
Marib					1			1
Sana'a				1			1	2
Total	124	1	4	29	9	1	16	184

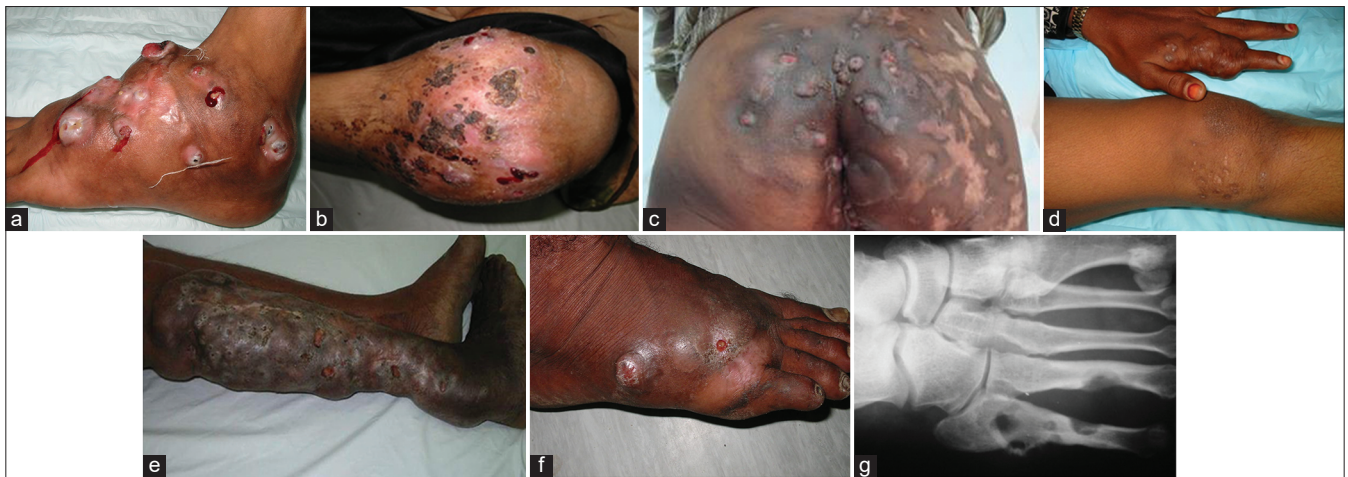

Figure 2: Eumycetoma caused by *Madurella mycetomatis* involving (a) foot, (b) knee, (c) gluteal region, (d) knee and hand, (e) leg, (f) foot, (g) X-ray of same patient showing medium sized well defined cavities.

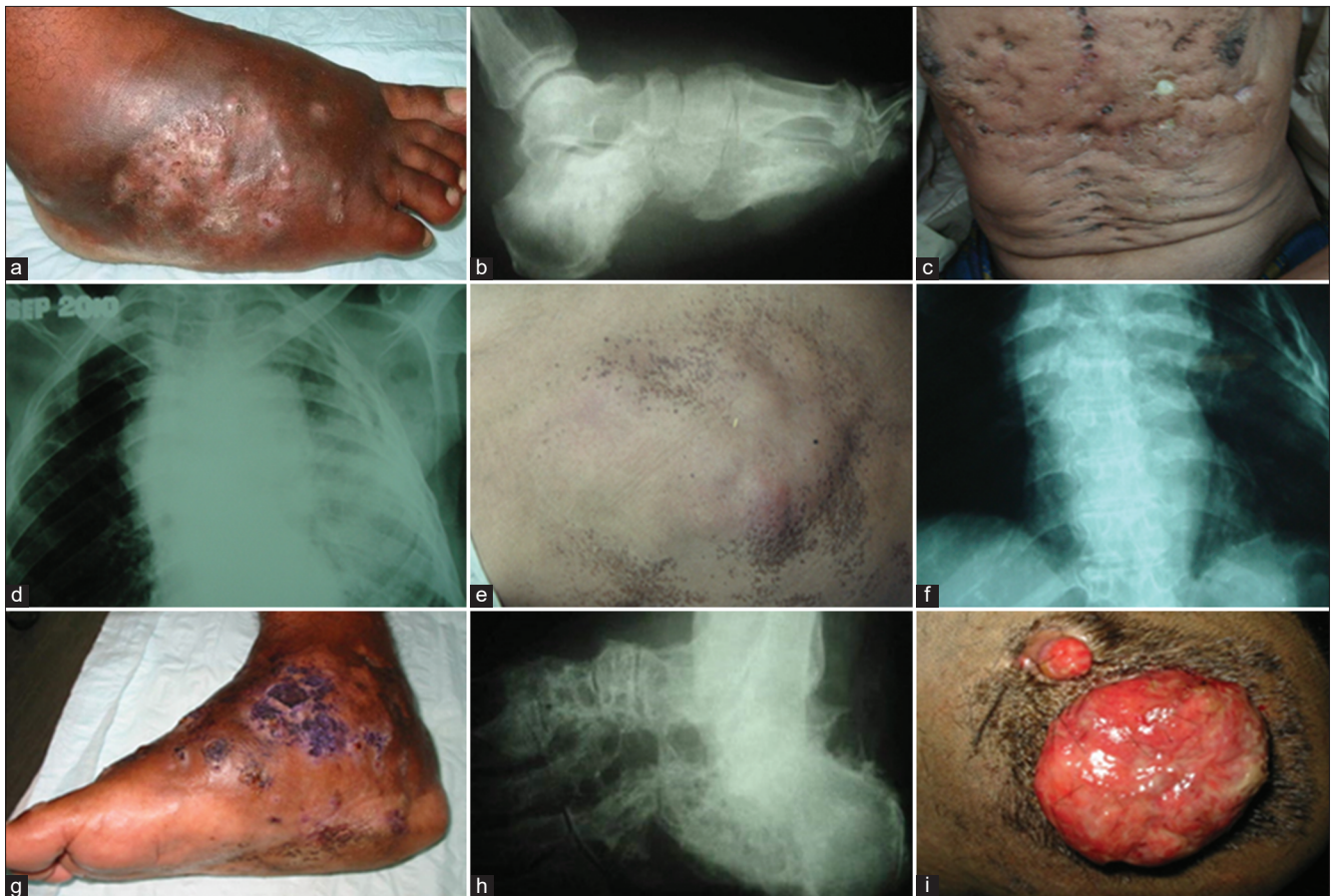


Figure 3: Actinomycetoma caused by *Streptomyces somaliensis* (a) foot (b) same patient, X – ray showing erosions of bones with small cavities, other patient of actinomycetoma caused by *Streptomyces somaliensis* with involvement of chest (c) lungs (d), involvement of spine leading to cold abscess (e & f) and Actinomycetoma of foot caused by *Nocardia* with extensive bone involvement (g & h) Actinomycetoma caused by *Actinomyces peletieri* on the scalp looking like pyogenic granuloma (i)

ranged between three years and 85 years. The most common age group was between 30 and 40 years and median age was 35 years. Age at onset ranged between two years and 75 years (median age 25 years). Duration of disease ranged from six months to 43 years. The majority of the patients were farmers. History of thorn prick or injury was recorded in eight patients.

Pain was noticed by 34 patients, heaviness of foot or hand was noticed in five, restriction of joint movement in five and fever in three.

Nodular and well-defined swellings were observed in 127 patients and diffuse lesions in 57. All but five patients had

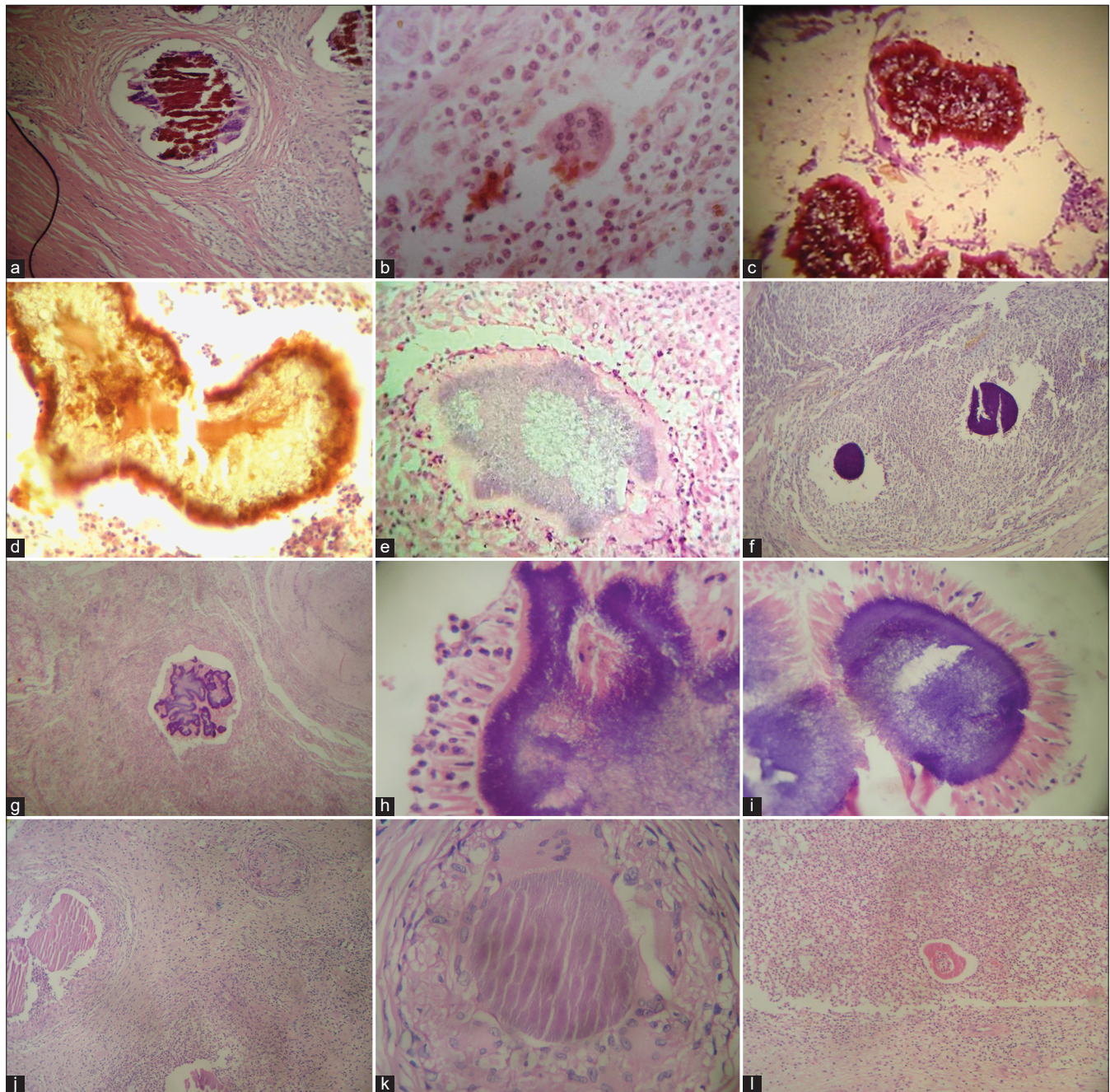


Figure 4: Histopathological sections showing (a) *M. mycetomatis* filamentous grain surrounded by neutrophils (type I reaction) along with epithelioid granuloma on right side (type II reaction), haematoxylin and eosin $\times 40$ (b) particles of grains engulfed by giant cells (type III reaction) haematoxylin and eosin $\times 40$, (c) vesicular grains of *M. mycetomatis* haematoxylin and eosin $\times 40$, (d) grain of *Leptospheria senegalensis* haematoxylin and eosin $\times 80$, (e) Grains of Pale grain fungus, haematosilin and eosin $\times 40$, (f) grains of *Actinomadura pelletieri*, haematoxylin and eosin $\times 40$, (g) *Actinomadura madurae* grain with vermiform appearance, haematoxylin and eosin $\times 10$, (h) *Actinomadura Madurae* grain with peripheral Splendore-Hoeppli material, haematoxylin and eosin $\times 40$, (i) *Actinomadura Madurae* small grain, haematoxylin and eosin $\times 40$, (j) *Streptomyces somaliensis* grain surrounded by a thick layer of neutrophils with clear space in between with epithelioid granuloma on right side, haematoxylin and eosin $\times 40$, (k) *S. somaliensis* big grain surrounded by giant cells trying to engulf the grain, haematoxylin and eosin $\times 40$, (l) *Nocardia* grain surrounded with abundant neutrophils and few plasma cells

multiple sinuses ranging from two to sixty two. Sinuses were closed in seven patients. Discharge was serosanguineous in 132 and purulent in 40 patients. Different coloured grains could be seen in the discharge of 140 patients and in biopsy specimens in 28 patients. Grains could not be seen with the naked eye in 16 patients but were recognized in KOH preparation and/or

histopathology. Grains were black in 125, yellowish in four, yellowish white in 25, white in 29 and red in one. Table 1 shows involvement of different sites of the body. Radiological examination revealed bone involvement in 53 patients.

After analysis of clinical features, examination of grains and evaluation of the results of routine investigations our cases

were classified as eumycetoma in 129 [Figures 2a-2f] and actinomycetoma in 55 patients [Figures 3a-3i]. Identification of causative agents was performed in all the cases by histopathology.

Histopathological studies

The causative agents identified by histopathology and their geographical distribution are given in Table 2. A brief description of the histopathological findings and characteristics of the grains of different causative organisms is detailed below.

Eumycetoma

Madurella mycetomatis (124 cases)

Grains were dark brown or black, 1–4 mm in size and embedded in brown matrix called cementing substance. Two types of grains were seen, filamentous in 109 patients [Figure 4a] and vesicular in 15 patients [Figure 4c]. Three types of tissue reactions were observed: Type 1: Adherence of neutrophils to the surface of grain leading to its destruction [Figure 4a]. Type 2: Fragmented grains and neutrophils cleared by macrophages and multinucleated giant cells [Figure 4b]. Type 3: Discrete well-defined epithelioid granuloma with Langhans giant cells [Figure 4a].

Leptosphaeria senegalensis (One case)

Haematoxylin & eosin stains: The grains were dark brownish black, 0.4–1 mm in size. Borders of the grains were uneven and crenated. Peripheral zone was deeply pigmented by dark brown cement in which numerous vesicles were immersed. Toward the central zone vesicles were few, while filaments were more and devoid of pigment and cement. Centre of the grains had abscesses containing bacteria [Figure 4d].

Pale grain fungi (Four cases)

The grains were yellowish, measuring 0.2–2 mm. Haematoxylin & eosin stain: Tissue reaction was predominantly neutrophilic. There was no clear space around the grains but they were surrounded by abundant neutrophils. Adjacent to these, a chronic granulomatous infiltrate with macrophages, plasma cells and foreign body giant cells was seen. The grains were composed of a dense network of thin hyphae which became larger with spores and vesicles as they approached the periphery. Cementing substance was absent. The grains took up eosin stain which was slightly deeper at the periphery [Figure 4e].

Actinomycetoma

Actinomyces madurae (Nine cases)

White or yellow grains. Haematoxylin & eosin stain: Grains varied in size from 150 to 450 µm. The grains were rounded, multi-lobed, or vermiform. Two types of grains, small and large were seen in the same section. Small grains were composed of dense filaments and stained deep blue with haematoxylin. Large grains were multi-lobed with irregular borders, which had peripheral bands that stained deep blue

while the centre stained as faint blue colour. Both types of grains were surrounded by an eosinophilic zone which showed radiating filaments and clubs (Splendore-Hoepli material). Spores, pigment and cementing substance were absent. Tissue reaction was mainly neutrophilic. A clear space was present around the grains. Next to the clear space, neutrophils were seen and granulation tissue was absent [Figures 4g-4i].

Streptomyces somaliensis (29 cases)

Yellow grains. Haematoxylin & eosin stains: The grains measured 0.5–1 mm, and were round or oval, occasionally multi-lobed, with an almost homogeneous appearance but usually showed cracks as a result of sectioning. Grains were lightly basophilic but tended to be eosinophilic towards the periphery. The grains showed a smooth border without clubs. The cement substance was abundant. Hyphal elements were seen as delicate faintly basophilic filaments in the cement. Pigment and spores were absent. Just around the grain a clear space was present along with a wider zone of neutrophilic infiltration. Next to it, an admixture of neutrophils, macrophages, plasma cells and giant cells was seen. Giant cells were both foreign body and Langhans type, attempting to engulf the grains. A narrow zone of granulation tissue with poor vascularity and fibrosis was seen at the periphery [Figures 4j and 4k].

Actinomyces pelletieri (One case)

Grains were red. Haematoxylin & eosin stain: Grains were small (60 – 150 microns), round and oval. Haematoxylin stained the grains dark violet. A narrow eosinophilic band surrounded the grains. Mycelial elements were not clearly seen. Spores and pigment were absent but cement like substance was present which stained dark blue. Tissue reaction was predominantly neutrophilic. Neutrophils were seen just around the grain and next to it were lymphocytes and macrophages. Fibrosis was absent with poor vascularity [Figure 4f].

Nocardia species (16 cases)

Grains were white or yellow measuring 0.1–0.2 mm. Differentiation of subspecies was not possible by histopathological study. Grains were round, oval or irregular with rounded edges. Haematoxylin & eosin stain: Grains stained eosinophilic and showed branched segmented filaments with indistinct walls. Spores, pigment and cementing substance were absent. Periphery of grains was fringed, clubbed. Grains were surrounded by abundant neutrophils. Plasma cells were also seen. Giant cells were absent. Vascularity of moderate degree was seen and fibrosis was absent [Figure 4l].

Radiological findings

Bone involvement was observed in 30 (23%) eumycetoma cases and 23 (43%) actinomycetoma patients. Duration of the disease in patients with bone involvement in eumycetoma cases was between three and 43 years while in actinomycetoma it was from one to 28 years. Radiological study in eumycetoma

cases revealed large and small well-defined cavities [Figure 2g] and in actinomycetoma cases, erosions of bones with small cavities were seen. We observed more severe and extensive bone involvement in actinomycetoma caused by *Nocardia* although the clinical appearance did not suggest it [Figure 3f and i].

Treatment and follow-up

Actinomycetoma

Co-trimoxazole (sulphamethoxazole 1600 mg and trimethoprim 320 mg) daily in two divided doses in adults and half the dose in children was given in 23 patients for four months to two years. Four patients showed complete remission in two years. Ten patients showed partial remission after four–12 months therapy and were later lost to follow-up. Nine patients could be followed up for four to six months and showed minimal improvement but were later lost to follow-up. This treatment, with initial addition of injection streptomycin 1 g daily (total dose 1 g per kg of body weight), was given to 30 patients for one and half years. Twenty four patients improved well. Six patients with big lesions needed excision or debulking for quicker response. Six patients showed only partial response. Modified Welsh regimen (amikacin 15 mg/kg/day i/v, 3 – 4 cycles of 21 days with interval of 15 days + co-trimoxazole (800 / 160 mg twice daily + rifampicin 10 mg/kg/day, from the start of therapy up to three months after the last amikacin cycle) was given to six patients who did not respond well to the above treatment and in two patients from the outset. All of them showed good response. Co-trimoxazole was further continued for three–six months and none of them showed recurrence in follow-up of six months to one year.

Eumycetoma

Ketoconazole 400 mg/day with interrupted courses of co-trimoxazole or other antibiotics according to bacterial culture/sensitivity was given to all 125 patients for four months to four years. Four patients were seen once only. 24 patients had excision followed by this therapy and 60 patients were initially given ketoconazole for two to three months, followed by excision and again followed by ketoconazole, with interrupted courses of antibacterial drugs for six to 12 months. Itraconazole was given in four patients who did not show good response to ketoconazole. Excision could not be performed in 19 patients either due to bigger size of the lesions or occurrence at sites which were difficult to operate, but debulking was done. Two patients needed amputation because of extensive bone involvement and poor response to drug therapy. Twenty patients refused operative procedures. Recurrence after excision was observed in seven patients and needed re-excision followed by drug therapy. Results were better in patients who received antifungal therapy for two to three months before excision and those who received itraconazole (which was not given to all patients as it was not in the hospital supply and most of the patients could not afford it).

Discussion

Yemen falls in the mycetoma belt (latitude between 15° S and 30° N). A maximum number of eumycetoma cases (79) were from Al-Hudaydah governorate, where the temperature is high (32–50°C) throughout the year and usual rainfall is 100 – 200 mm. In the previous study from the same region, the maximum number of actinomycetoma cases were from Hajjah governorate, but in the present study, the number is almost equal in Hajjah and Al-Hudaydah governorates. The *Nocardia* cases of actinomycetoma were maximum (13) in Hajjah governorate and *Streptomyces somaliensis* cases were maximum (19) in Al-Hudaydah. The total number of actinomycetoma cases was higher in Hajjah and the other regions where the temperature is low and rainfall is high. A higher incidence of *Madurella mycetomatis* and *Streptomyces somaliensis* has been previously reported to be in areas with low and medium rainfall whereas a higher incidence of *Nocardia* has been reported in higher rainfall regions.³

Cardenas-de la Gorges *et al.*¹⁰ (Mexico) studied the different contributing ecological factors like rainfall, temperature, vegetation and soil type and found that actinomycetoma caused by *Actinomadura palletieri*, *Actinomadura Madurae* and *Nocardia* were found in places with cooler weather and high rainfall. We also recorded such cases in similar weather conditions. Sami *et al.*¹¹ from Sudan also studied different ecological factors including thorny plants in relation to mycetoma and found similar associations. We also found similar associations of different ecological factors including thorny plants like acacia.

Sex incidence, male 145:female 39 (3.71:1) was almost similar to the previous study from this region⁹ and other previous reports.^{12,13} A much higher incidence (5:1) in males has been reported in studies conducted elsewhere.¹⁴⁻¹⁶ A higher incidence in males is justifiable due to more outdoor activities (farming etc.), where chances of infection are more. A lower incidence in females may also be due to inhibition of *Madurella mycetomatis* by progesterone.¹⁷ The most common age group was between 30 and 40 years and median age was 35, similar to the results of previous studies.^{9,12-14} Most of our patients were farmers as has been reported before.^{9,12} History of injury or thorn prick was recorded only in eight patients but unnoticed injury is common in farmers. Relation to thorn prick and mycetoma has been noticed earlier by several investigators.^{12,18-20} A role of guinea worm extraction, leaving an open wound, a suspected mode of inoculation has been reported in a study from Rajasthan, India.¹² In a recent study from Sudan, role of ticks has been suspected in transmission of mycetoma as *Madurella mycetomatis* was detected in ticks.²¹ Although a majority of the patients were asymptomatic, pain, and fever due to secondary infection was noticed in a few patients while a few others had restriction of joint movement when joints or nearby regions were involved. Similar results have been recorded earlier.^{9,12} The majority

of the patients had painless lesions, as the nerves are not involved in mycetoma.³

Lesions were circumscribed in the majority of the cases of eumycetoma, while actinomycetoma patients had ill-defined lesions as reported in previous studies.^{3,9,12} The most common site of involvement was the foot, similar to previous reports.^{3,9,12} Out of these 92 (64.8%) were eumycetoma and 50 (35.2%) were actinomycetoma. Extrapodal involvement is more common in actinomycetoma.^{9,12} In one of our patients with actinomycetoma of scalp due to *Actinomadura pelletieri*, initial look was similar to pyogenic granuloma. The diagnosis could be confirmed after histopathology. Such a presentation has not been reported earlier. Another patient of actinomycetoma due to *Streptomyces somaliensis* had initial lesions on the chest wall, which later involved the lungs and then the spinal bones leading to cold abscesses. We did not come across such a presentation in the reviewed literature although intra spinal mycetoma with paraplegia caused by *Madurella mycetomatis* and *Streptomyces somaliensis*, without skin or bone involvement has been reported before.²² Although, the colour of grains is mostly diagnostic, it cannot be used always to distinguish between eumycetoma and actinomycetoma. However, black grains are always of fungal origin (e.g. *Madurella mycetomatis*); red grains are specific for the *Actinomadura pelletieri*. White-yellow grains could be either fungal or actinomycotic in nature. Similar observations were reported by Murrey.²³

Histopathology studies revealed that the most common causative agent was *Madurella mycetomatis* as reported in the only previous study from the same region⁹ and in other previous studies from different parts of the world.^{3,12,14,15,24,25} The histopathological findings were similar to the previous study reports.^{24,26,27} The characteristics of the grains revealed the diagnosis of the causative species. Fahal *et al.* described three types of inflammatory response in cases of eumycetoma due to *Madurella mycetomatis*.²⁸ We observed similar findings in most of our cases due to *Madurella mycetomatis* [Figures 4a and 4b]. Joshi *et al.* described different type of inflammatory reactions in actinomycetoma cases as observed in our cases due to *Streptomyces somaliensis* [Figures 4j and 4k].²⁹ Identification of different causative agents of mycetoma can be done by histopathology although culture studies are needed to reconfirm the results. The major advantages of histopathology are speed, and elimination of risk of misdiagnosis due to isolation of contaminant fungi, but we cannot differentiate subtypes of *Nocardia* and pale grain fungus. Histopathology remains one of the main tools for the diagnosis of mycetoma in resource limited settings. Siddig *et al.* compared the results of histopathology and culture and found that the histological examination results were correct in 714 (97.5%) out of 750 patients infected with *Madurella mycetomatis*, in 133 (93.6%) out of 142 patients infected with *Streptomyces somaliensis*, in 53 (74.6%) out of 71 patients infected with *Actinomadura madurae* and in 12 (75%) out of 16 patients infected with *Actinomadura pelletieri*.³⁰

Bone involvement was more common and started early in cases of actinomycetoma. Bony changes were quite specific, as has been reported earlier,^{8,12} and helpful in distinguishing actinomycetoma from eumycetoma. We observed more severe and extensive bone involvement in actinomycetoma caused by *Nocardia* although the clinical appearance did not suggest it [Figures 3g and 3h]. Magnetic resonance imaging (MRI) gives better information but it was not available.

In cases of actinomycetoma, initially we tried co-trimoxazole monotherapy and complete remission was observed in four cases after two years and partial improvement in others. Similar results were noticed in the previous study from the same region⁹ and a few other reports.³¹⁻³³ Later, we tried a combination of co-trimoxazole with injection streptomycin and this combination showed better results. Similar results have been reported before.³⁴ Nasher *et al.* tested *in vitro* sensitivity of 13 antibiotics against ten cases of actinomycetoma caused by *Streptomyces somaliensis* and found that rifampicin was the most effective one, followed by erythromycin, tobramycin, fusidic acid and streptomycin.³⁵ Ameen and Arenas reviewed the potential of different new treatment regimens.³⁶ Welsh *et al.* tried amikacin alone and in combination of co-trimoxazole in treatment of actinomycetoma.³⁷ Later Damle *et al.* tried modified Welsh regimen which showed better results. We also observed the best results with this therapy tried in few cases of actinomycetoma.³⁸

Most of the cases of eumycetoma could be controlled with prolonged ketoconazole therapy along with excision. Results were better in patients who received antifungal therapy for two to three months prior to excision and followed by prolonged antifungal therapy. Results were better in patients who received itraconazole. Fahal *et al.* concluded in their study that initial pre-operative treatment with itraconazole may be recommended for eumycetoma patients to enhance encapsulation and localization of lesions, which can facilitate wide local excision, thus avoiding unnecessary massive mutilating surgery.³⁹ Newer antifungal drugs voriconazole, isavuconazole and posaconazole also have good response in eumycetoma.⁴⁰ Ahmed *et al.* evaluated the *in vitro* activity of the new antifungal agent ravuconazole against *Madurella mycetomatis*.⁴¹ The drug showed excellent *in vitro* activity against all tested strains and its prodrug, E1224 might be a potential new therapeutic option for eumycetoma caused by *Madurella mycetomatis*.

Limitations

Identification of different causative agents was done by histopathology and could not be reconfirmed by culture.

Conclusion

Incidence of mycetoma seems to be quite high in north-west Yemen with highest incidence in Al-Hudaydah governorate. The present study revealed that eumycetoma is more common, with maximum cases due to *Madurella mycetomatis*. Causative species could be identified by histopathological studies in all the cases but further sub-classification of pale grain fungus

and *Nocardia* was not possible. In actinomycetoma, cases due to *Streptomyces somaliensis* were most common followed by *Nocardia*. Drug treatment alone gave satisfactory results in the most of the cases of actinomycetoma while eumycetoma cases needed prolonged antifungal therapy with excision/debridement.

Declaration of patient consent

Institutional Review Board (IRB) permission was obtained for the study. Informed consent was also taken from all the patients.

Financial support and sponsorship

Nil.

Conflicts of interest

There are no conflicts of interest.

References

- Carter HV. On a new and striking form of fungus disease principally affecting the foot and prevailing endemically in many parts of India. *Trans Med Phys Soc Bombay* 1860;6:104-42.
- Welsh O, Verra-Vabrera L, Salina-Carmona MC. Mycetoma. *Clin Dermatol* 2007;25:195-202.
- Mahgoub ES, Murray IG, editors. Mycetoma. London: William Heinemann Medical Books; 1973. p. 1-116.
- Clemov FG. Mycetoma (Madura foot) in the Yemen. *BMJ* 1906;1:918-9.
- Yu AM, Zhao S, Nie LY. Mycetomas in Northern Yemen: Identification of causative organisms and epidemiologic considerations. *Am J Trop Med Hyg* 1993;48:812-7.
- Fahmi OA, Bin Bisher SA, Baraba RO, Bafageer SS. Mycetoma in South Yemen. *JBMS* 2021;2:259-63.
- Lorenz G, Bernhardt H. Eumycotic mycetoma of the foot (maduromycosis). *Zentralbl Allg Pathol* 1985;130:363-7.
- Al-Ali AA, Keshgar TQ, Nathani PG, Moawad MK. Radiological manifestations of Madura foot in the eastern province of Saudi Arabia. *Ann Saudi Med* 1997;17:298-301.
- Khatri ML, Al-Halali HM, Fouad M, Saif SA, Vyas MC. Mycetoma in Yemen: Clinicoepidemiologic and histopathologic study. *Int J Dermatol* 2002;41 586-93.
- Cardenas-de la Garza JA, Welsh O, Cuellar-Barboza A, Suarez-Sanchez KP, Cruz-Gomez LG, Cruz-Valadez ED, et al. Climate, soil type, and geographic distribution of actinomycetoma cases in Northeast Mexico: A cross-sectional study. *PLoS One* 2020;15:e0232556.
- Samy AM, van de Sande WW, Fahal AH, Peterson AT. Mapping the potential risk of mycetoma infection in Sudan and south Sudan using ecological niche modeling. *PLoS One* 2014;8:e3250.
- Sharma JC, Joshi KR, Vyas MC, Sankhala SS, Gupta SP. Mycetoma in Jodhpur division of Rajasthan. *Indian J Orthop* 1990;24:17-26.
- Gonzalez-Ochoa A. Mycetoma caused by *Nocardia brasiliensis* with note on the isolation of the causative organism from soil. *Lab Invest* 1962;11:1118-23.
- Abbott PH. Mycetoma in the Sudan. *Trans R Soc Trop Med Hyg* 1956;50:11-24.
- Rey M. Les Mycetoma dans L'ouest African, These. Paris: R. Foulon; 1961.
- Latapi F, Ortiz Y. Los micetoma en Mexico. Algunos datos nuevos clinicos and epidemiologicos relativos a 197 casos. In: *Memorias del Primes Congreso, Mexicano de Dermatologia, Mexico D.F.; 1963. p. 126-44.*
- Mendez-Tovar LJ, de Bieve C, Lopez-Martinez R. Effects des hormones sexuelles humaines sur le development *in vitro* des agents d'eumycetomes. *J Mycol Med* 1991;1:141.
- Bocarro JE. On mycetoma. *Trans Bombay Med Congr* 1909;20:324-32.
- Gammel JA. The etiology of maduromycosis with a mycologic report on two new species observed in the United States. *Arch Derm Syphilol* 1927;15:241-84.
- Abbott PH. Mycetoma. A Clinical and Epidemiological Study. Dissertation for the Degree of MD. Cambridge: Cambridge University; 1954.
- Azrag RS, Bakhiet SM, Almalik AM, Mohamed AH, Fahal AH. Is Mycetoma a Vector Borne Disease: The First Report on the Detection of *Madurella mycetomatis* in ticks, bioRxiv; 2019.
- Arhab MA, El Hag IA, Abdul Gader AF, Sidik HR. Intra spinal mycetoma. Report of two cases. *Am J Trop Med Hyg* 1997, 56:27-9.
- Murray IG. Some aspects of medical mycology in the tropics. *Trans R Soc Trop Med Hyg* 1966;60:544-1.
- Vyas MC, Arora HL, Joshi KR. Histopathological identification of various causal species of mycetoma prevalent in North West Rajasthan (Bikaner region). *Indian J Dermatol Venereol Leprol* 1985;51:76-9.
- McGinnis MR. Mycetoma. *Dermatol Clin* 1996;14:97-104.
- Winslow DT, Steen FG. Consideration in the histologic diagnosis of mycetoma. *Am J Clin Pathol* 1964;42:164-9.
- Verghese A, Klokke AH. Histologic diagnosis of species of fungus causing mycetoma. *Indian J Med Res* 1966;54:524-30.
- Fahal AH, El Toum EA, Hasan AM, Mahgoub E, Gumaa S. The host tissue reaction to *Madurella mycetomatis* -new classification. *J Med Vet Mycol* 1995;33:15-7.
- Joshi KR, Solanki A, Joshi YR, editors. Mycetoma. India: Agrobios; 2000. p. 1-107.
- Siddig EE, Mahmoud NA, Bakhiet SM, Abdallah OB, Mekki SO, El Davi NI, et al. The accuracy of histopathological and cytopathological techniques in the identification of the mycetoma causative agents. *PLoS Negl Trop Dis* 2019;13:e0007056.
- Mahgoub ES, Murray IG. Progress Report on Project R 2048. London: Medical Research Council; 1971.
- Lynch JB. Mycetoma in Sudan. *Ann R Coll Surg Engl* 1964;35:319-40.
- Sharma JC, Joshi KR, Vyas MC, Sankhala SS, Gupta SP. A clinicopathological and mycological study of mycetoma involving upper extremity at Jodhpur, India. *Indian J Med Sci* 1988;42:103-8.
- Mahgoub ES. Medical management of mycetoma. *Bull World Health Organ* 1976;54:3003-11.
- Nasher MA, Hay RJ, Mahgoub ES, Gumma SA. *In vitro* studies of antibiotic sensitization of *Streptomyces somaliensis*-a cause of human actinomycetoma. *Trans R Soc Trop Med Hyg* 1989;82:245-8.
- Ameen M, Arenas R. Developments in the management of mycetoma. *Clin Exp Dermatol* 2008;34:1-7.
- Welsh O, Saucedo E, Gonzalez J, Ocampo J. Amikacin alone and in combination with trimethoprim-sulfamethoxazole in the treatment of actinomycotic mycetoma. *J Am Acad Dermatol* 1987;17:443-8.
- Damle DK, Mahajan PM, Pradhan SN, Belgaumkar VA, Gosavi AP, Gosavi AP, et al. Modified Welsh regimen: A promising therapy for actinomycetoma. *J Drugs Dermatol* 2008;7:853-6.
- Fahal AH, Raman IA, El-Hassan AM, Rahman ME, Zijlstra EE. The safety and efficacy of itraconazole for the treatment of patients with eumycetoma due to *Madurella mycetomatis*. *Trans R Soc Trop Med Hyg* 2011;105:127-32.
- Welsh O, Al-Abdely HM, Salinas-Carmona MC, Fahal AH. Mycetoma medical therapy. *PLoS Negl Trop Dis* 2014;8:e3218.
- Ahmed SA, Kloezen W, Duncanson F, Zijlstra EE, de Hoog GS, Fahal AH, et al. *Madurella mycetomatis* is highly susceptible to ravuconazole. *PLoS Negl Trop Dis* 2014;8:e2942.