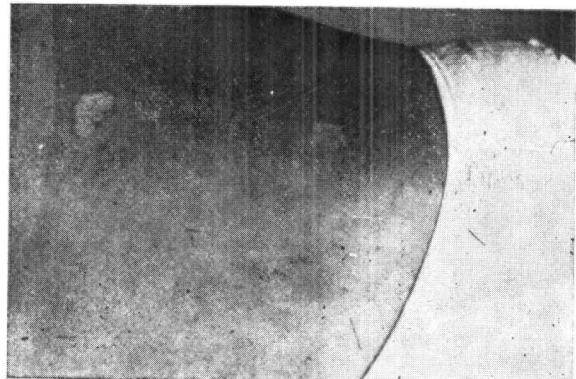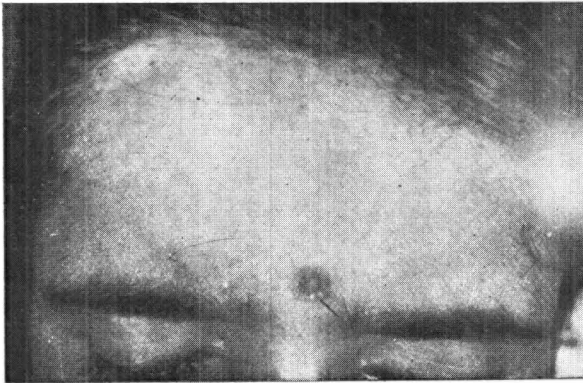


WHAT IS YOUR DIAGNOSIS ?

Twenty - four year old female patient presented with the following complaints :

1. skin lesions on face since 6 months ;
2. progressive scarring patchy alopecia of scalp, pigmentation on exposed parts of the body, pain on finger tips on exposure to cold and occasional joint pains for 2 years ; and
3. chronic productive cough and low grade fever for 2 years. Patient was given a course of antituberculous treatment at her place but had no relief of symptoms.

Examination of the skin showed mild hyperpigmentation on exposed parts of the body. Erythematous scaly plaques were seen on left cheek, nose, forehead and upper back. Scarring alopecia was present on various parts of the scalp. Examination of lungs revealed harsh breath sounds. Liver was palpable 1 cm below costal margin. There was no tenderness. No other abnormalities were detected.



Differential diagnosis :

1. Progressive systemic sclerosis
 2. Systemic lupus erythematosus
 3. Sarcoidosis
 4. Disseminated tuberculosis with lupus vulgaris.
-

Repeated sputum for direct smear and culture for A.F.B. were negative. Serum electrophoresis was normal. L.E. cells were negative on 2 occasions. Chest X-ray showed chronic inflammatory changes in both lungs and patchy area of consolidation in the right middle lobe area. Skin biopsy showed naked tubercloid granulomas. Lung biopsy showed similar granulomatous inflammation in the middle and lower lobes. Liver biopsy was normal. Tests for delayed hypersensitivity with PPD, mumps antigen and D.N.C.B. gave negative results. Cultures from the skin and lung tissue were negative for A.F.B. Kveim test was not done as antigen was not available.

Investigations revealed the following :

Final diagnosis : Sarcoidosis