

## WHAT IS YOUR DIAGNOSIS?

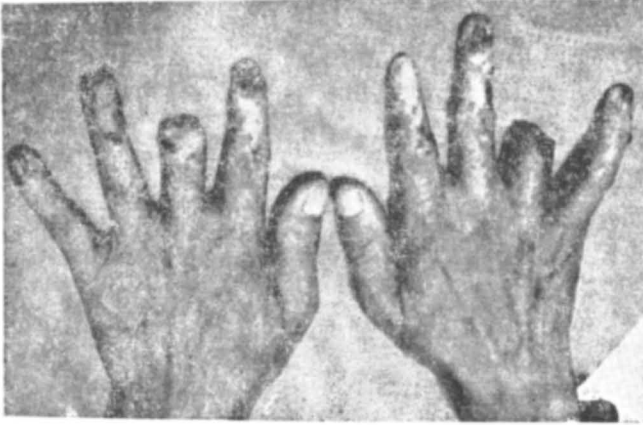


Fig. 1

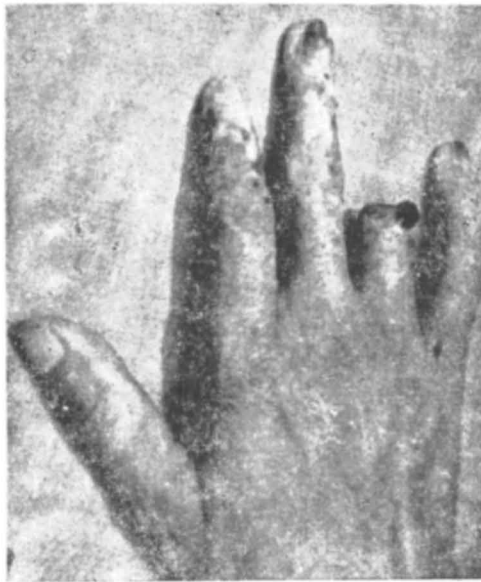

Fig. 2

Fingers of both hands except the thumbs show ulcers and crusted and hyperkeratotic lesions. The skin over these fingers is hyperpigmented and depigmented having atrophy scarring and telangiectasia. The right ring finger and left middle finger have been amputated due to non-healing ulceration.

### Differential Diagnosis :

1. Trophic changes secondary to peripheral neuropathy ;
2. Gangrene and necrosis secondary to peripheral vascular disease ;
3. Radiation effects ;
4. Collagen disease.

*(Diagnosis overleaf)*

**History :**

40 year old male showed the above clinical features of 8 years duration. Peripheral pulsations of both hands are normal. No evidence of peripheral neuropathy. He is a radiographer working in a small hospital for 11 years. Patient never took proper precautions for his hands while handling the X-ray machines. Biopsies of some of the keratotic and crusted lesions revealed both premalignant and frank malignant changes. Other routine investigations are within normal limits.

**Diagnosis : Radiation effects**

Radiation causes two types of changes on skin ; radiation dermatitis following radiation exposure and late radiation changes usually more than two years after radiation exposure. The late radiation changes are necrosis and malignant changes. Radiation necrosis usually heals with conservative topical treatment resulting in atrophic scars and telengectasia. The malignant lesions should be treated with electro-coagulation or surgery but not by radiation therapy. Possible leukemia in these patients must be ruled out by thorough investigations and should be borne in mind in the follow up of these patients.