

Hair manifestations of endocrine diseases: A brief review

Keshavamurthy Vinay, Gitesh U. Sawatkar, Sunil Dogra

Department of Dermatology, Venereology and Leprology, Postgraduate Institute of Medical Education and Research, Chandigarh, India

Abstract

Hair disorders are common in clinical practice and depending upon social and ethnic norms, it can cause significant psychosocial distress. Hair growth, cycling and density are regulated by many endogenous factors, mainly circulating hormones. Thus, diseases affecting the endocrine system can cause varied changes in physiological hair growth and cycling. Diagnosis and treatment of these disorders require a multidisciplinary approach involving a dermatologist, gynecologist and an endocrinologist. In this review, we briefly discuss the influence of hormones on the hair cycle and hair changes in various endocrine disorders.

Correspondence:

Dr. Sunil Dogra,
Department of Dermatology,
Venereology and Leprology,
Postgraduate Institute of Medical
Education and Research,
Sector 12, Chandigarh - 160 012,
India.
E-mail: sundogra@hotmail.com

Key words: Endocrine disorders; hirsutism; hyperandrogenism; hypertrichosis; patterned hair loss

Introduction

Hair is an important structure of the body playing a significant role in the psychosocial personality of an individual. However, endocrine dysfunction can affect the hair growth, cycling and density and its examination can give an insight to the underlying cause. Hormonal disturbances can cause hypertrichosis, hirsutism or alopecia. In this review, we briefly discuss the influence of hormones on the hair cycle and hair changes in various endocrine disorders.

Hormonal influence on hair

Androgens

In the development of secondary sexual characters

At puberty, the vellus follicles in the axillae and groin in both males and females, and of the beard area and trunk of males are converted to terminal hair by the action of androgens.¹ At certain sites, androgens increase the duration of hair cycle, alter the ability of keratinocytes to divide, increase pigmentation and increase the size of the dermal papilla.

In patterned hair loss

Circulating androgens play an important role in the pathogenesis and progression of patterned hair loss. This is

based on the observation that eunuchs and castrated boys do not develop male patterned hair loss, unless supplemented by testosterone.² Also genetically males with androgen insensitivity syndrome do not go bald. In male patterned hair loss, di-hydro testosterone and testosterone bind to androgen receptors present on the cells of dermal papilla and alter the production of soluble regulatory factors that influence the growth and activity of other cells, such as hair follicle keratinocytes. This leads to progressive miniaturization of scalp hairs.³

The role of androgens in female patterned hair loss is controversial. Not all studies have found raised androgens in patients with female patterned hair loss. In a study comprising 109 women with female patterned hair loss, 38.5% were found to have a clinical or biochemical evidence of hyperandrogenism.⁴ Of the 187 women with hair loss, 67% of those with hair loss alone and 84% who were also hirsute, were found to have some degree of biochemical androgen excess.⁵ In patients with normal androgen levels, it is hypothesized that there is increased formation of potent

This is an open access journal, and articles are distributed under the terms of the Creative Commons Attribution-NonCommercial-ShareAlike 4.0 License, which allows others to remix, tweak, and build upon the work non-commercially, as long as appropriate credit is given and the new creations are licensed under the identical terms.

For reprints contact: reprints@medknow.com

How to cite this article: Vinay K, Sawatkar GU, Dogra S. Hair manifestations of endocrine diseases: A brief review. Indian J Dermatol Venereol Leprol 2018;84:528-38.

Received: November, 2017. **Accepted:** March, 2018.

Access this article online	
Quick Response Code:	Website: www.ijdv.com
	DOI: 10.4103/ijdv.IJDVL_671_17

androgens (di-hydro testosterone and testosterone) from their precursors in the skin (cutaneous hyperandrogenism).⁶

Oestrogen

Oestrogens are required for the normal development of pubic and axillary hair in females. However, its function in scalp hair growth in both sexes is less clear as is its role in female patterned hair loss. The increased prevalence of female patterned hair loss after menopause suggests a stimulatory role for oestrogens in hair growth. High systemic oestrogen levels in pregnancy are speculated to partially account for the prolongation of anagen, whereas post-partum fall in oestrogen levels may partially account for telogen gravidarum.⁷ On the other hand, in murine models, the administration of parenteral and topical oestrogen agonists has been shown to produce a profound and prolonged inhibition of hair growth through telogen arrest, whereas oestrogen antagonists stimulated hair growth through the initiation of anagen.⁸ Thus, unlike androgens, the role of oestrogen on hair cycling is controversial and has not been adequately studied.

Growth hormone

Growth hormone potentiates the effect of androgen on sexual hair growth. About 5-fold more testosterone is required to induce axillary hair in growth hormone-deficient than in growth hormone-sufficient hypogonadal boys.¹ Its effects are probably mediated through insulin like growth factor-1.

Insulin

Insulin and the insulin like growth factors system have a role in stimulating hair growth and may act in concert with the androgens. Hyperinsulinaemia may also induce 5 α reductase activity and cause increased production of di-hydro testosterone.

Prolactin

Prolactin induces catagen in male occipital scalp hair follicles,⁹ while promoting hair shaft elongation in female fronto-temporal scalp hair follicles.¹⁰ Clinically, prolactin

excess is associated with hirsutism, probably because of stimulation of hyperandrogenism.

Thyroid

Thyroid receptors have been found on outer root sheath cells and it appears to regulate the frequency of the hair cycle.¹¹ Hypothyroidism leads to decreased frequency of anagen, whereas hyperthyroidism leads to thin hairs.

Vitamin D-retinoid X receptor system

Vitamin D is necessary for postnatal cycling of the hair follicle.¹² Individuals born with vitamin D receptor deletions suffer from postnatal alopecia that cannot be corrected by calcium administration.

Definitions¹³

Hirsutism: Presence of excessive terminal hair in androgen-dependent areas of the female body. [Figure 1]

Hyperandrogenemia: Abnormally high amounts of androgens detectable in the blood.

Hyperandrogenism: Clinical manifestation of hyperandrogenemia in the form of hirsutism, acne, seborrhea, alopecia, infertility etc.

Cutaneous hyperandrogenism: Cutaneous clinical signs of hyperandrogenism present without documented evidence of hyperandrogenemia [Figure 2].

Hypertrichosis: Presence of excessive body hair in non-androgen dependent manner [Figure 3].

Endocrine disorders causing abnormal/excessive hair growth

Hirsutism

Hirsutism, a clinical sign for hyperandrogenemia, is a frequent reason of cosmetic embarrassment, poor self-esteem, and psychological distress for women world over.¹⁴

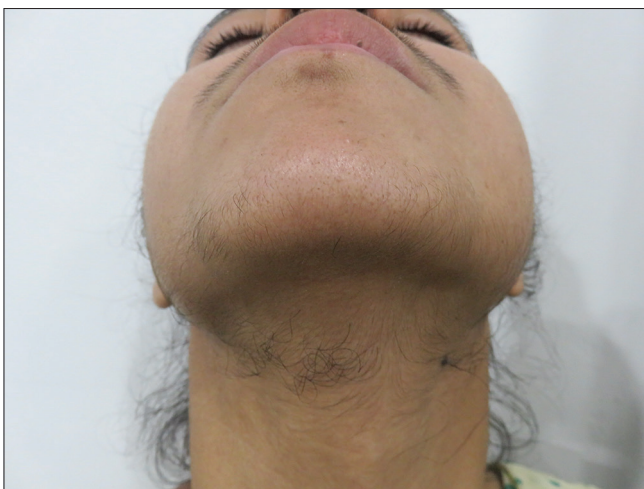

Figure 1a: A case of hirsutism showing growth of terminal hair in the androgen dependent sites

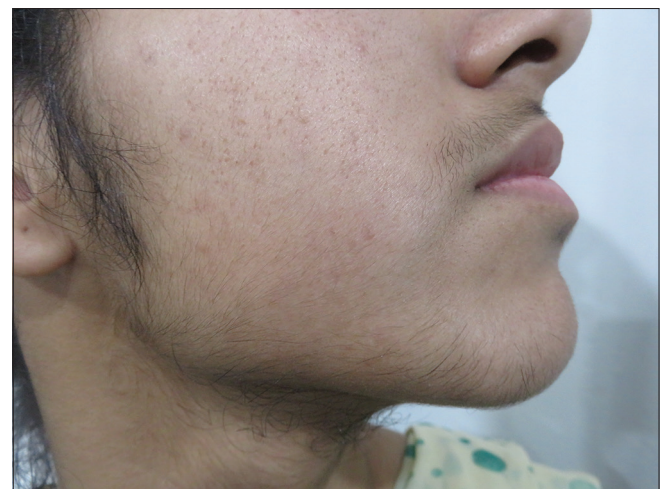

Figure 1b: A case of hirsutism showing growth of terminal hair in the androgen dependent sites

Epidemiology

The prevalence of hirsutism ranges from 4.3 to 10.8% in blacks and whites, but appears to be somewhat lower in Asians.¹⁵ The prevalence and severity of hirsutism decrease with increasing age (except among post-menopausal women).¹⁶

Causes

Hirsutism is a manifestation of increased action of androgens at the hair follicle. Hirsutism is observed in 70–80% of patients with hyperandrogenemia and in turn, 70–80% of hirsute patients have hyperandrogenemia.¹⁶ The most common cause of hirsutism is polycystic ovarian syndrome, accounting for >70% of cases.¹⁷ Depending on ethnicity and the geographic area, idiopathic hirsutism constitutes 5–17% of the patients with hirsutism. In approximately 1–8% of the women with hirsutism, the underlying cause is non-classical congenital adrenal hyperplasia because of 21-hydroxylase deficiency.¹⁸ Other causes are summarized in Figure 4.¹⁷

Pathophysiology

Vellus hair is converted to terminal hair by the action of androgens at puberty. Increase level of circulating androgens in hyperandrogenemic states stimulates the differentiation of androgen dependent vellus hair into terminal hair. Various other mechanisms postulated in idiopathic hirsutism are^{6,11}

1. Exaggerated peripheral 5α reductase activity
2. Androgen receptor polymorphism

3. Altered androgen metabolism
4. Insulin resistance
5. Decreased sex hormone binding globulin levels
6. Lower aromatase levels.

Approach

A detailed history regarding the age at onset, duration, menstrual irregularities, weight gain, diabetes, symptoms of hyperandrogenemia (acne, seborrhea, alopecia etc.), symptoms of virilization (deepening of voice, increased muscularity, breast atrophy etc.), drug intake, galactorrhea, family history etc., should be obtained. Functional causes usually show a peripubertal onset, slow progression, positive family history in some and signs of virilization are extremely rare. On the other hand, androgen secreting tumors show sudden onset, rapid progression, signs and symptoms of virilization in middle aged or elderly females.¹⁵ A detailed physical examination of the patient should be done. All the androgen dependent areas should be assessed for the severity of hirsutism. Truncal hirsutism is a better indicator of polycystic ovarian syndrome than facial hirsutism.¹⁹ Signs of virilization such as clitoromegaly or thinning of scalp hair should be checked for. Abdomen should be palpated for a mass. Blood pressure of the patient should be recorded and body mass index calculated.

Severity assessment and investigations

The subjective and objective assessment of hirsutism is summarized in Table 1.²⁰

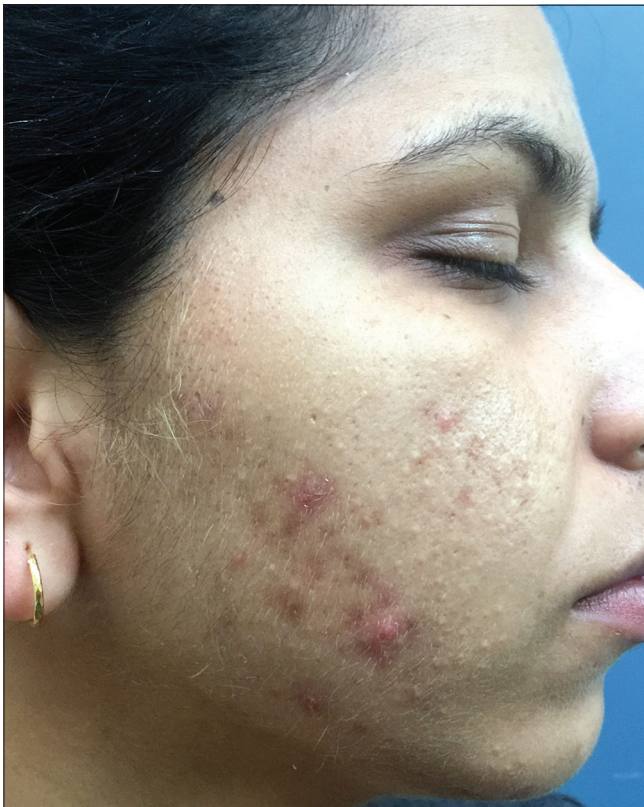

Figure 2: A case of polycystic ovarian syndrome with hirsutism, seborrhea and hormonal acne

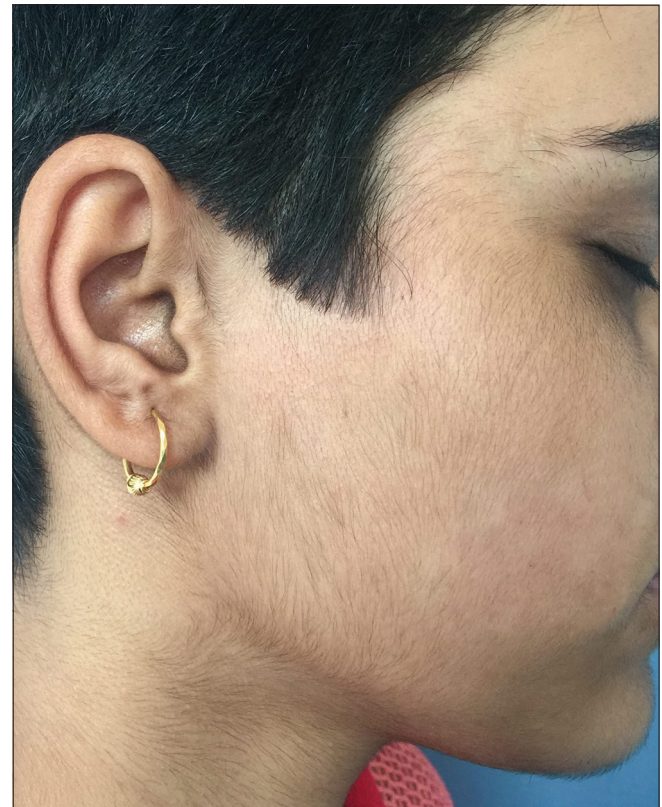

Figure 3: Hypertrichosis secondary to use of systemic cyclosporine and corticosteroids for treatment of alopecia areata

The relevant investigations are tabulated in Table 2.²¹⁻²³

Treatment

Management of clinically important hirsutism consists of a dual approach: medical therapy of the underlying abnormality and physical methods to remove the terminal hairs already present.^{24,25} The medical and physical methods are summarized in Tables 3 and 4 respectively.

Table 1: Severity assessment of hirsutism

Subjective method

Modified Ferriman-Gallwey score

Scale to be assigned to each of the 9 areas -

0 - no visible terminal hair

1 - Minimally visible terminal hair

2 - More than minimal terminal hair not equivalent to adult male

3 - Terminal hair as in a not very hairy male

4 - Terminal hair as in a fully virilized adult male

(Cutoff ≥ 8 ; 8-15 - mild, 15-26 - moderate, 26-36 - severe)

Objective method

Weighing the hairs obtained from dry shaving the area of interest

Measuring the outer diameter of clipped hairs

Assessing the density of terminal hairs either by direct counting or by videomicroscopy

Photographic record of the degree of hirsutism

Measuring the rate of growth using calibrated capillary glass tubes

Vellus index: fraction of vellus hairs in 100 shaven hairs. This is low in hirsute women

Summary of medical treatment

1. Oral contraceptive pills provide effective contraception recommended for the concomitant use of anti-androgens, and are quite useful for the regularization of menstrual bleeding in women with polycystic ovarian syndrome, which will also reduce the risk of endometrial hyperplasia.
2. Oral contraceptive pills/anti-androgen combinations are more efficacious than oral contraceptive pills monotherapy.²⁶ Oral contraceptive pills are usually combined in majority of women and anti-androgen monotherapy should be used only when strict contraception is ensured.²⁷
3. Evidence suggests a potency gradient with anti-androgenic oral contraceptive pills cyproterone acetate >drospirenone >chlormadinone acetate and third-generation oral contraceptive pills being superior to second-generation oral contraceptive pills for hirsutism (desogestrel >levonorgestrel)²⁵
4. Among anti-androgens, flutamide appears to have highest efficacy and finasteride the lowest¹⁵
5. Metformin has beneficial effects in overweight or obese patients and is especially helpful in adolescents with polycystic ovarian syndrome²⁸
6. In women with congenital adrenal hyperplasia, prolonged remission after withdrawal of anti-androgen

Table 2: Investigations in cases of hirsutism²²⁻²⁴

	Investigation	Comment
Hormonal Profile	Testosterone	Serum level may be mild to moderately raised in PCOS or CAH but a level more than 200ng/ml is suggestive of a virilizing tumor. Free testosterone level is more sensitive than the measurement of total testosterone for establishing androgen excess.
	Free androgen index	Free androgen index is a ratio of total serum testosterone divided by the SHBG (Free androgen index=total testosterone (nmol/L) *100/SHBG (nmol/L)). It is intended to give a guide to the free testosterone and levels more than 5 are indicative of PCOS
	Anti-mullerian hormone	Anti-mullerian hormone is expressed by granulosa cells of the ovary during the reproductive years, and limits the formation of primary follicles by inhibiting excessive follicular recruitment by FSH. It is a marker of ovarian reserve and is elevated in cases of PCOS
	Gonadotropins	LH and FSH level measurement is useful in diagnosing PCOS. An LH/FSH value >3 is diagnostic
	Prolactin	It may be increased in hypothalamic disorders, pituitary tumors and also in 25% of PCOS patients
	Dehydroepiandrosterone	A serum value >700 µg/dl always indicates an adrenal cause. Although levels of dehydroepiandrosterone are increased in about 30-35% of PCOS patients, its measurement does not add significantly to the diagnosis of PCOS.
	17-OH Progesterone	This serum marker is unique for CAH. The measurement should be done between 0700 and 0900 hours in the early follicular phase of the menstrual cycle. Levels less than 200 ng/dl excludes the disease. Mildly increased levels between 300 and 1,000 ng/dl require an ACTH stimulation test
Biochemical	24-hour urine free cortisol	When Cushing's syndrome is suspected
	Thyroid stimulating hormone	To rule out hypothyroidism as a cause
	Fasting and postprandial Plasma glucose	To rule out concomitant metabolic syndrome
	Fasting insulin levels Fasting lipid profile	
Radiological	Ultra sonography of pelvis	PCOS can be diagnosed by ovarian volume >10 ml, >25 follicles 2-9 mm in diameter. 22 String of pearl appearance may be seen
	MRI or CT abdomen and pelvis	To rule out adrenal or ovarian tumor

ACTH: adrenocorticotrophic hormone, CAH: congenital adrenal hyperplasia, FSH: follicle stimulating hormone, LH: luteinizing hormone, PCOS: polycystic ovarian syndrome, SHBG: sex hormone binding globulin

Table 3: Medical treatment of hirsutism^{25,26,28}

Drug	Mechanism of action	Dosage	Side effects	Comments
Oral contraceptive pills	Inhibition of pituitary gonadotropin, increase in SHBG	35 µg ethinyl estradiol + progesterone. 1 tablet per day for 21 days of cycle, followed by 7 day pill free period.	Gastrointestinal distress, weight gain, emotional lability, thromboembolic phenomena etc.	Corner stone of medical treatment. Combination with neutral progestins such as desogestrel should be preferred.
Spirolactone	Anti-androgen. Competitive inhibitor of dihydrotestosterone, inhibits 5-alpha reductase activity, Increase SHBG, weak progestin	50-200 mg/day Start at 50 mg twice a day	Hyperkalemia, gynecomastia, irregular menses, hypotension, liver dysfunction, feminization of male fetus	First line anti-androgen. Strict contraception mandatory. Monitor electrolytes and BP every 2-4 weeks. Contraindicated in breast cancer
Cyproterone acetate	Progestin with anti-androgen activity. Competitive inhibitor of 5alpha reductase activity, Decrease LH secretion, increase androgen metabolism	50-100 mg at bedtime on days 5-15. In combination with ethinyl estradiol in a dose of 2mg.	Nausea, depression, weight gain, irregular menses, feminization of male fetus	Strict contraception recommended for atleast 3 months after stopping treatment. LFTs to be monitored
Flutamide	Anti-androgen; androgen receptor blocker	125-250 mg two to three times per day	Hepatotoxicity, feminization of male fetus	Strict contraception. No longer recommended
Finasteride	5-alpha reductase (type 2) inhibitor	2.5-7.5 mg/day	Gastrointestinal distress, decreased libido, dry skin	Pregnancy category X drug. Monitor LFTs
Leuprolide acetate	GnRH agonist. Suppresses ovulation	5 mg intramuscular monthly with 25-50 µg estradiol transdermally	Decreased bone density, atrophic vaginitis, hot flushes	Pregnancy category X drug. Use only for short periods
Metformin	Insulin sensitizing drug	1000-2500 mg daily	Gastrointestinal distress, lactic acidosis	Not recommended for hirsutism alone. Monitor LFTs and RFTs. Useful mainly in PCOS
Eflornithine	Irreversible inhibitor of L-ornithine decarboxylase, a polyamine that is critical to the regulation of cell growth and differentiation within the hair follicle.	13.9% cream twice a day	None	Recommended for use in mild cases of facial hirsutism. Takes 8 weeks for its effects to manifest and 8 weeks for its effects to revert after withdrawal.

GnRH: gonadotropin releasing hormone, LFT: liver function test, LH: luteinizing hormone, PCOS: polycystic ovarian syndrome, SHBG: sex hormone binding globulin

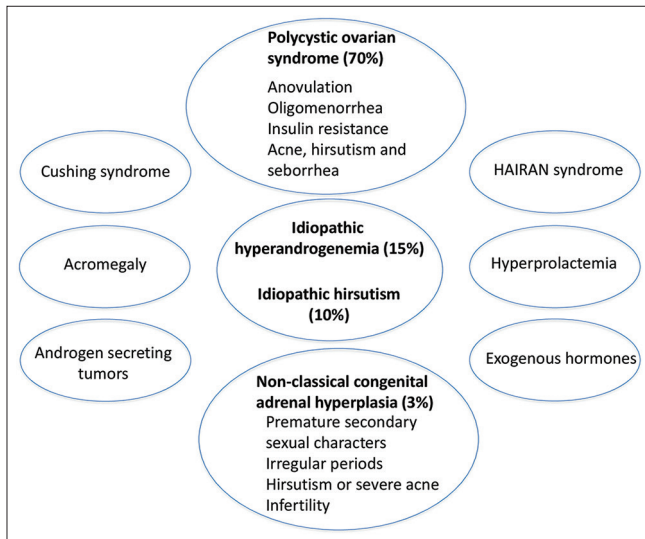


Figure 4: Causes of hirsutism

therapy may be obtained by the addition of glucocorticoids

- For all pharmacological therapies, a trial of 6 months is suggested before any changes in the medication can be made²⁷
- For women undergoing photoepilation, addition of

eflornithine cream (13.9%) is suggested for a more rapid response.²⁷

Hypertrichosis [Figure 3]

The causes of hypertrichosis are varied and can be congenital and acquired. Unlike hirsutism, where endocrine abnormalities are the predominant cause, only a minority of cases of acquired hypertrichosis has an endocrine cause. The important endocrine causes of acquired hypertrichosis are Cushing’s syndrome [Figure 3], acromegaly and hypothyroidism.²⁹ The exact mechanism by which endocrine disturbances cause hypertrichosis is not known, but their effect on hair growth and cycling may have a role. The speculated mechanisms are (a) switching of vellus to terminal hairs or (b) prolongation of the anagen duration.³⁰

The treatment is mainly directed at treatment of the underlying endocrine dysfunction. Significant cosmetic improvement can be obtained by physical treatment modalities [Table 4], which are usually combined with medical therapy.

Endocrine disorders causing or associated with hair loss
Patterned hair loss

Sex hormones play an important role in the development of patterned hair loss in both males and females. male patterned

Table 4: Physical methods of hair removal^{25,26,28}

Technique	Advantages	Disadvantages	Comment
Bleaching	Hydrogen peroxide softens the hairs, Inexpensive	Skin irritation, Ineffective	Temporary camouflaging. Sufficient in mild cases.
Shaving	Easy, inexpensive, effective	Quick regrowth, risk of folliculitis, beard stubble, ingrowing hair	Temporary surface removal. Sufficient in mild cases.
Depilatories	Quick, inexpensive, effective	Quick regrowth, skin irritation	Lack of safety studies for chemical depilatories in pregnancy
Plucking	Inexpensive, regrowth takes relatively longer time	Painful, folliculitis, ingrown hairs, post inflammatory hyperpigmentation, scarring	Temporary epilation of hair. Sufficient in mild cases
Waxing	Regrowth takes weeks	Painful, folliculitis, thermal burns	Temporary epilation of hair. Sufficient in mild cases
Electrolysis	Permanent reduction by destroying the dermal papilla	Painful, repeated treatments, expensive, scarring and pigment changes	Labor intensive. Best suited for limited areas
Laser and intense pulsed light	Permanent reduction, efficient	Repeated treatments, expensive, scarring, pigment disturbances	Based on photo thermolysis and is the main stay of treatment. Best response with lighter complexions and darker hair

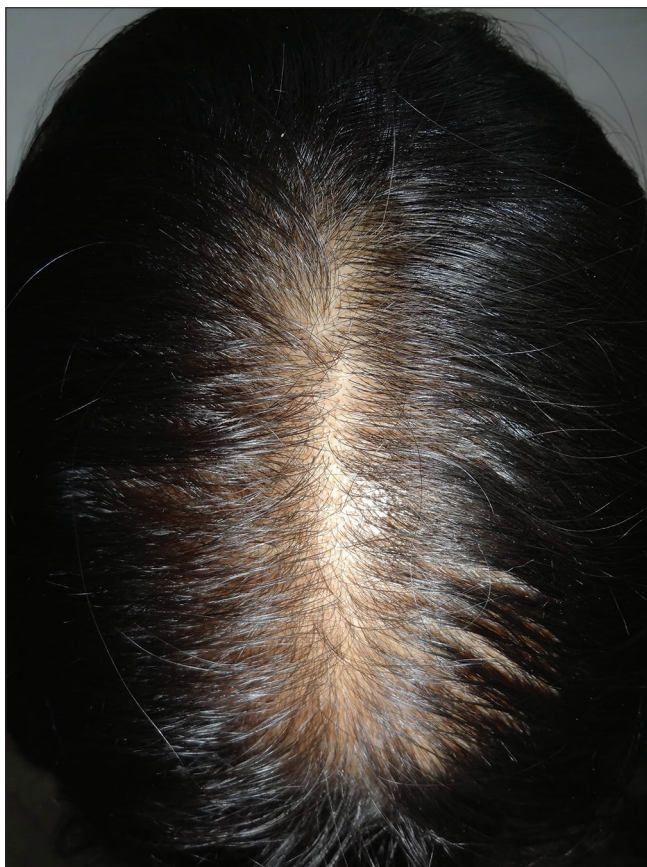

Figure 5a: Female patterned hair loss exhibiting thinning of hair over the crown

hair loss was thought to occur in men with normal androgen levels and is predominantly caused by genetic polymorphism of androgen receptor. However, recent studies evaluating the hormonal profile of early androgenetic alopecia in men have found hormonal disturbances akin to polycystic ovarian syndrome.³¹

Female patterned hair loss

Female patterned hair loss is characterized by progressive miniaturization of the hair follicle, usually with characteristic

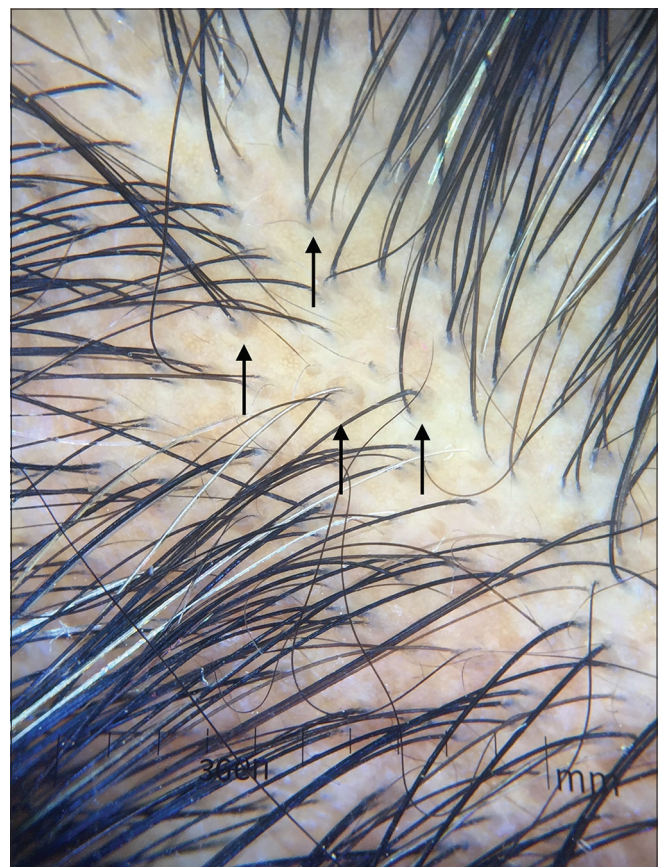


Figure 5b: Dermatoscopic features showing peri-follicular brownish discoloration in early female patterned hair loss (arrow). Anisotrichia and vellus hairs can also be appreciated

pattern distribution that occurs in genetically predisposed females and rarely with endocrine disturbances [Figure 5a].

Epidemiology

The actual prevalence of female patterned hair loss ranges from 6 to 64.4% and appears to be somewhat lower in Asians.³² There are two peaks of occurrence in female patterned hair loss, 3rd and 5th decades. There is an age associated increase in the prevalence of female patterned hair loss, with 1.3%

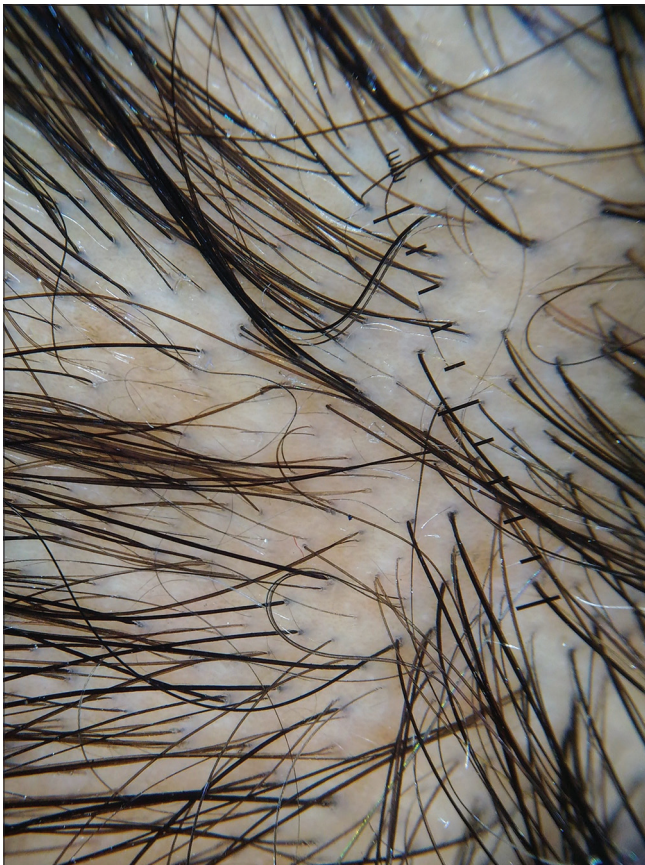

Figure 5c: More advanced female patterned hair loss showing anisotrichia with variation in the hair shaft diameter, vellus hair and a large number of follicular units with only one emerging hair shaft

in the age group of 18-29 years, increasing to 10.3% in the seventh decade and 11.8% thereafter.³³

Etiopathogenesis and role of endocrine disturbances

Female patterned hair loss like male patterned hair loss is a multifactorial entity. It tends to occur in genetically pre-disposed patients with altered hair follicle cycling leading to the transformation of terminal to shorter and finer vellus hair follicles. Under the influence of sex hormones (explained above), there is progressive reduction in the size of the dermal papilla, with reduction in the anagen duration and prolongation of telogen.³²

Evaluation

A complete gynecological history including menarche, menstrual cycle (regular / irregular), menopause, amenorrhoea, the use of oral or systemic hormonal pills, should be done to exclude influencing hormonal dysregulation or associated underlying disorders (e.g. hormone-sensitive tumor). Examination should focus on features of hyperandrogenism (hirsutism, acne or seborrhea). Trichoscopic features including hair shaft thickness heterogeneity, thin hairs, yellow dots, perifollicular discoloration (the peripilar sign), an increased proportion of vellus hairs, and a large number of follicular

units with only one emerging hair shaft are suggestive of patterned hair loss [Figure 5b and 5c].³⁴ If the history and clinical examination are indicative of androgen excess, free androgen index has to be performed. Free testosterone and free androgen index seem to be sensitive for the detection of hyperandrogenaemia. Free androgen index levels of 5 and above are indicative for polycystic ovarian syndrome. In such a scenario, other disorders presenting with clinical and / or biochemical signs of hyperandrogenism such as congenital adrenal hyperplasia, androgen-secreting tumors or Cushing syndrome need exclusion.

Clinical features and classifications

Female patterned hair loss has a chronic and a progressive course. Patients usually complain of increased thinning of hair over the vertex, but characteristically the frontal hairline is preserved [Figure 5]. Early in the disease phase patients may also complain of increased shedding and hair pull test may be positive. This is because of the increased conversion of anagen hairs to telogen. At times, an episode of telogen effluvium can unmask sub-clinical female patterned hair loss. The most widely used in classification system for female patterned hair loss is Ludwig's classification. In stage I, there is thinning of hair from the anterior part of the crown with rarefaction of the part width (SAHA syndrome).³⁵ Stage II is seen with advancing age where rarefaction is more pronounced. Camouflage of the denuded areas is no longer possible.³⁵ In stage III there is complete rarefaction of scalp but a fringe of frontal hair usually persists (adrenal diseases and androgen secreting tumors). Other staging systems used are Olsen and Hamilton-Norwood classification.

Treatment

Various drugs have been tried in the treatment of female patterned hair loss, but many of these treatment modalities lack sufficient evidence. There is a need for high quality studies comparing different treatment modalities for more robust data.³⁶

Medical treatment

1. **Minoxidil:** Topical minoxidil (2% or 5%) has been widely used to treat female patterned hair loss. A recent Cochrane systemic review for female patterned hair loss concluded that minoxidil treatment results in moderate increase in hair re-growth compared with placebo.³⁶ Minoxidil 5% twice daily was marginally better than 2% twice daily in patient assessment, but was also associated with increase adverse effects like pruritus, local irritation, and hypertrichosis.³⁷ In another study 5% minoxidil foam once daily was as effective and with lower rates of local intolerance than 2% minoxidil solution twice daily.³⁸
2. **Antiandrogens:** Cyproterone acetate (50-100mg/day), spironolactone (100-200mg/day), flutamide (100-200mg/day) and finasteride (1 or 5mg/day) are all used in the treatment of female patterned hair loss. Vexiau *et al.*³⁹ compared cyproterone

acetate (50mg) with topical 2% minoxidil and found better outcome with minoxidil. However, cyproterone acetate was more effective when clinical or biochemical evidence of hyperandrogenemia was present. In a randomized control trial comparing cyproterone acetate (50mg), finasteride (5mg) and flutamide (250mg) in hyperandrogenic alopecia, Carmina *et al*.⁴⁰ found improvement in Ludwig's score only in flutamide treated group.

Cosmetic concealment³²

Camouflaging products and other concealment techniques can effectively mask areas of visible hair loss. Commonly used techniques for mild to moderate hair loss include hair fibers (keratin-made), masking lotions, topical shading, and scalp spray thickeners. For moderate–severe loss, integration hairpiece or wig may be used. Hair loss can also be covered using hats, scarves, bandanas, and turbans.

Telogen effluvium

Telogen effluvium, a common cause of hair loss is an abnormality of hair cycling that results in excessive loss



Figure 6: A case of chronic telogen effluvium due to hypothyroidism

of telogen hairs [Figure 6]. The important endocrine causes of telogen effluvium are hyper and hypothyroidism, Addison's disease and hypopituitarism. In addition, thyroid disorders are associated with madarosis and multiple endocrine neoplasia type 2B is associated with disorganized eyelashes.⁴¹

Approximately 50% and 33% of patients of hyper and hypothyroidism respectively have diffuse telogen hair loss.⁴² The severity of hair loss is not directly related to the severity of the endocrine abnormality and telogen effluvium can be the only presentation of sub-clinical hypothyroidism.

Telogen effluvium can be clinically suspect in patients with acute/insidious onset diffuse hair loss with positive hair pull test. Trichogram or skin biopsy, if done, shows increased in telogen hairs. Trichoscopy has limited value in diagnosis of telogen effluvium. Frequent, but not specific, findings include the presence of empty hair follicles, a predominance of follicular units with only one hair, perifollicular discoloration (the peripilar sign), and upright re-growing hairs.³⁴ Early female patterned hair loss can mimic telogen effluvium, but can be differentiated on histopathology by miniaturization of hair follicles and decrease terminal to vellus hair ratio. At times, acute telogen effluvium can unmask latent female patterned hair loss.

Telogen effluvium is usually reversible, except in long-standing cases where the hair follicles are said to

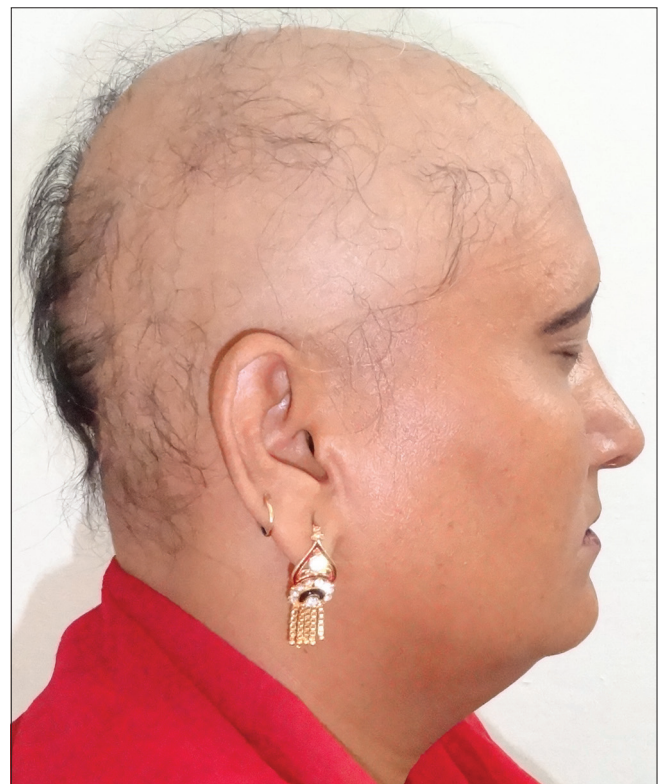

Figure 7: A female patient of alopecia sub-totalis, who also suffered from hypothyroidism

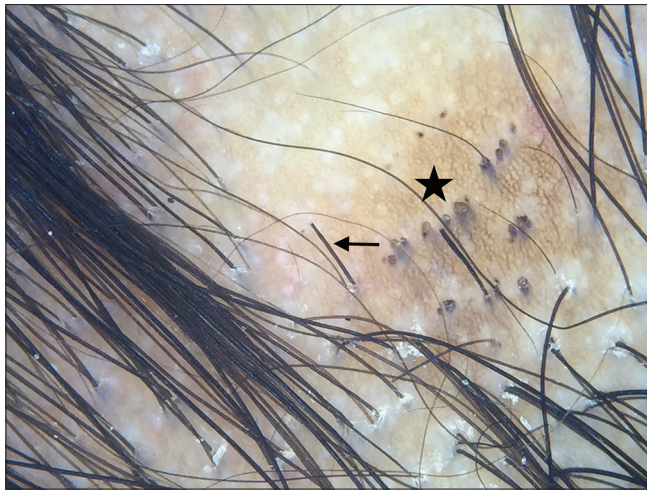


Figure 8a: Dermatoscopic features of alopecia areata. The consistent feature of active alopecia areata is black dots (asterisks) which represent broken hair shaft at the level of infundibulum. Adjoining broken hair shaft can also be appreciated (arrow)

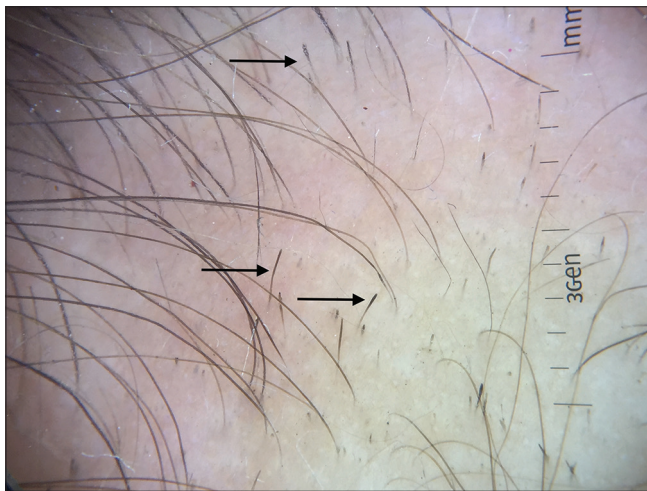


Figure 8b: Dermatoscopic features of alopecia areata. Other typical feature of acute and active alopecia areata is exclamation hair which are thin at the proximal end and thicker distally

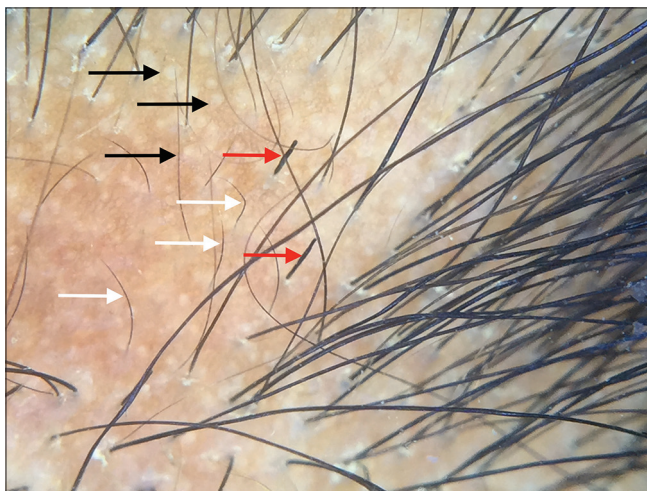


Figure 8c: Dermatoscopic features of alopecia areata. Long standing alopecia areata is characterized by yellow dots (black arrow) and vellus hair (white arrow). Broken hairs can also be appreciated at the periphery (red arrow)

have atrophied. Treatment of underlying endocrine disorder is of utmost importance. Topical minoxidil 2-5% and iron supplementation in patients with low serum ferritin can be used to stimulate hair growth.⁴³

Alopecia Areata

Alopecia areata is an immunologically mediated disease characterized by sudden-onset, non-scarring, patchy hair loss (involving any hair bearing area) with significant cosmetic impact [Figure 7]. It's a fairly common disease with a lifetime risk of around 2%. Trichoscopic evaluation of early and active alopecia areata shows black dots [Figure 8a], exclamation hair and broken hair [Figure 8b], whereas longstanding inactive alopecia areata shows yellow dots and vellus hairs [Figure 8c].³⁴

The disease has long been known to occur with various autoimmune disorders like rheumatoid arthritis, Type 1 diabetes mellitus, vitiligo, systemic lupus erythematosus, thyroiditis, pemphigus vulgaris, pernicious anemia and coeliac disease. Milgraum *et al.*⁴⁴ reported thyroid function test abnormalities or thyroid auto-antibodies in 24% of 45 evaluated children with alopecia areata. In adult alopecia areata patients, thyroid peroxidase antibody was found in 17.7% of cases.⁴⁵ Children with personal medical history of Down syndrome, atopy or a family medical history of thyroid diseases benefit from screening for thyroid dysfunction.⁴⁶ Screening is also recommended in patients with concerning features on physical examination such as goiter, constipation, cold intolerance, or in the patient's medical history, such as deviation on the growth chart.⁴⁶

Treatment of alopecia areata depends on the disease extent. Limited patchy hair loss can be managed by potent topical corticosteroids or intralesional corticosteroids.⁴⁷ Extensive patchy hair loss/alopecia sub-totalis/alopecia totalis may require systemic corticosteroids and contact immunotherapy.⁴⁷

Congenital Papular Atrichia and Vitamin-D Dependent Rickets Type II

Congenital papular atrichia is a rare autosomal recessive disorder caused due to mutation in the hairless gene, in which the scalp and body hairs are irreversibly lost soon after birth and are replaced by papular or milia like lesions over the scalp. Vitamin-D dependent rickets type II is an autosomal recessive inheritable disorder caused due to mutation in the vitamin D receptor in which target organs fail to respond to hormonal form of vitamin D. Interestingly, in addition to rickets, patients with vitamin-D receptor also manifest alopecia with few patients showing papular lesions. The alopecias associated with Vitamin-D dependent rickets type II and congenital papular atrichia show striking clinical and microscopic similarities and cannot be differentiated on the basis of clinical and histological studies.⁴⁸ Further studies suggested that this

common phenotypic expression is due to their impact on common signaling pathway in normal hair growth, the product of hairless gene acting as a co-repressor of expression of vitamin D receptor.⁴⁹

Conclusion

Hair changes are common in various endocrine diseases and can be the first clinical sign of underlying occult endocrinopathy. Dermatologist, endocrinologist and allied specialties should have knowledge of these changes for effective diagnosis and treatment.

Declaration of patient consent

The authors certify that they have obtained all appropriate patient consent forms. In the form the patient(s) has/have given his/her/their consent for his/her/their images and other clinical information to be reported in the journal. The patients understand that their names and initials will not be published and due efforts will be made to conceal their identity, but anonymity cannot be guaranteed.

Financial support and sponsorship

Nil.

Conflicts of interest

There are no conflicts of interest.

References

- Rosenfield RL. Hirsutism and the Variable Response of the Pilosebaceous Unit to Androgen. *J Invest Dermatol Symp Proc* 2005;10:205–8.
- Hamilton JB. Male hormone stimulation is prerequisite and an incitement in common baldness. *Am J Anat* 1942; 451.
- Bahta AW, Farjo N, Farjo B, Philpott MP. Premature Senescence of Balding Dermal Papilla Cells *In Vitro* Is Associated with p16INK4a Expression. *J Invest Dermatol* 2008; 128:1088–94.
- Futterweit W, Dunaif A, Yeh HC, Kingsley P. The prevalence of hyperandrogenism in 109 consecutive female patients with diffuse alopecia. *J Am Acad Dermatol* 1988; 19:831–6.
- Vexiau P, Chaspoux C, Boudou P, Fiet J, Abramovici Y, Rueda MJ, et al. Role of androgens in female-pattern androgenetic alopecia, either alone or associated with other symptoms of hyperandrogenism. *Arch Dermatol Res* 2000; 292:598–604.
- Orfanos CE, Adler YD, Zouboulis CC. The SAHA Syndrome. *Horm Res Paediatr* 2000; 54:251–8.
- Simpson D, Curran MP, Perry CM. Letrozole: a review of its use in postmenopausal women with breast cancer. *Drugs* 2004; 64:1213–30.
- Ohnemus U, Uenalan M, Inzunza J, Gustafsson J-Å, Paus R. The Hair Follicle as an Estrogen Target and Source. *Endocr Rev* 2006;27:677-706.
- Foitzik K, Krause K, Conrad F, Nakamura M, Funk W, Paus R. Human Scalp Hair Follicles Are Both a Target and a Source of Prolactin, which Serves as an Autocrine and/or Paracrine Promoter of Apoptosis-Driven Hair Follicle Regression. *Am J Pathol* 2006;168:748-56.
- Langan EA, Ramot Y, Goffin V, Griffiths CEM, Foitzik K, Paus R. Mind the (Gender) Gap: Does Prolactin Exert Gender and/or Site-Specific Effects on the Human Hair Follicle? *J Invest Dermatol* 2010;130:886-91.
- Azziz R, Carmina E, Sawaya ME. Idiopathic Hirsutism I. *Endocr Rev* 2000; 21:347–62.
- Amor KT, Rashid RM, Mirmirani P. Does D matter? The role of vitamin D in hair disorders and hair follicle cycling. *Dermatol Online J* 2010; 16:3.
- Madnani N, Khan K, Chauhan P, Parmar G. Polycystic ovarian syndrome. *Indian J Dermatology, Venereol Leprol* 2013; 79:310.
- Sharma N, Mahajan V, Jindal R, Gupta M, Lath A. Hirsutism: Clinico-investigative profile of 50 Indian patients. *Indian J Dermatol* 2008;53:111.
- Escobar-Morreale HF, Carmina E, Dewailly D, Gambineri A, Kelestimir F, Moghetti P, et al. Epidemiology, diagnosis and management of hirsutism: a consensus statement by the Androgen Excess and Polycystic Ovary Syndrome Society. *Hum Reprod Update* 2012; 18:146–70.
- Li R, Qiao J, Yang D, Li S, Lu S, Wu X, et al. Epidemiology of hirsutism among women of reproductive age in the community: a simplified scoring system. *Eur J Obstet Gynecol Reprod Biol* 2012; 163:165–9.
- Kopera D, Wehr E, Obermayer-Pietsch B. Endocrinology of hirsutism. *Int J Trichology* 2010; 2:30.
- Unluhizarci K, Kaltsas G, Kelestimir F. Non polycystic ovary syndrome-related endocrine disorders associated with hirsutism. *Eur J Clin Invest* 2012; 42:86–94.
- Schmidt TH, Khanijow K, Cedars MI, Huddleston H, Pasch L, Wang ET, et al. Cutaneous Findings and Systemic Associations in Women With Polycystic Ovary Syndrome. *JAMA Dermatology* 2016; 152:391.
- Yildiz BO, Bolour S, Woods K, Moore A, Azziz R. Visually scoring hirsutism. *Hum Reprod Update* 2010; 16:51–64.
- Goodman NF, Cobin RH, Futterweit W, Glueck JS, Legro RS, Carmina E. American association of clinical endocrinologists, american college of endocrinology, and androgen excess and polycystic ovarian syndrome society disease state clinical review: guide to the best practices in the evaluation and treatment of polycystic ovary syndrome-part I. *Endocr Pract* 2015; 21:1291–300.
- Hahn S, Kuehnel W, Tan S, Kramer K, Schmidt M, Roesler S, et al. Diagnostic value of calculated testosterone indices in the assessment of polycystic ovary syndrome. *Clin Chem Lab Med* 2007; 45:202–7.
- Iliodromiti S, Kelsey TW, Anderson RA, Nelson SM. Can Anti-Müllerian Hormone Predict the Diagnosis of Polycystic Ovary Syndrome? A Systematic Review and Meta-Analysis of Extracted Data. *J Clin Endocrinol Metab* 2013; 98:3332–40.
- Mofid A, Seyyed Alinaghi SA, Zandieh S, Yazdani T. Hirsutism. *Int J Clin Pract* 2007; 62:433–43.
- Somani N, Turvy D. Hirsutism: An Evidence-Based Treatment Update. *Am J Clin Dermatol* 2014; 15:247–66.
- Swiglo BA, Cosma M, Flynn DN, Kurtz DM, Labella ML, Mullan RJ, et al. Clinical review: Antiandrogens for the treatment of hirsutism: a systematic review and metaanalyses of randomized controlled trials. *J Clin Endocrinol Metab* 2008; 93:1153–60.
- Martin KA, Chang RJ, Ehrmann DA, Ibanez L, Lobo RA, Rosenfield RL, et al. Evaluation and Treatment of Hirsutism in Premenopausal Women: An Endocrine Society Clinical Practice Guideline. *J Clin Endocrinol Metab* 2008; 93:1105–20.
- Ibáñez L, Oberfield SE, Witchel S, Auchus RJ, Chang RJ, Codner E, et al. An International Consortium Update: Pathophysiology, Diagnosis, and Treatment of Polycystic Ovarian Syndrome in Adolescence. *Horm Res Paediatr* 2017; 88:371–95.
- Shibli-Rahhal A, Van Beek M, Schlechte JA. Cushing's syndrome. *Clin Dermatol* 2006; 24:260–5.
- Wendelin DS, Pope DN, Mallory SB. Hypertrichosis. *J Am Acad Dermatol* 2003; 48:161–82.
- Sanke S, Chander R, Jain A, Garg T, Yadav P. A Comparison of the Hormonal Profile of Early Androgenetic Alopecia in Men With the Phenotypic Equivalent of Polycystic Ovarian Syndrome in Women. *JAMA Dermatology* 2016; 152:986.
- Singal A, Sonthalia S, Verma P. Female pattern hair loss. *Indian J Dermatology, Venereol Leprol* 2013; 79:626.
- Wang TL, Zhou C, Shen YW, Wang XY, Ding XL, Tian S, et al. Prevalence of androgenetic alopecia in China: a community-based study in six cities. *Br J Dermatol* 2010; 162:843–7.
- Mubki T, Rudnicka L, Olszewska M, Shapiro J. Evaluation and diagnosis of the hair loss patient: part II. Trichoscopic and laboratory evaluations. *J Am Acad Dermatol* 2014; 71:431.e1-431.e11.

35. Camacho-Martínez FM. Hair Loss in Women. *Semin Cutan Med Surg* 2009; 28:19–32.
36. van Zuuren EJ, Fedorowicz Z, Carter B. Evidence-based treatments for female pattern hair loss: a summary of a Cochrane systematic review. *Br J Dermatol* 2012; 167:995–1010.
37. Lucky AW, Piacquadio DJ, Ditre CM, Dunlap F, Kantor I, Pandya AG, et al. A randomized, placebo-controlled trial of 5% and 2% topical minoxidil solutions in the treatment of female pattern hair loss. *J Am Acad Dermatol* 2004; 50:541–53.
38. Blume-Peytavi U, Hillmann K, Dietz E, Canfield D, Garcia Bartels N. A randomized, single-blind trial of 5% minoxidil foam once daily versus 2% minoxidil solution twice daily in the treatment of androgenetic alopecia in women. *J Am Acad Dermatol* 2011; 65:1126–1134.e2.
39. Vexiau P, Chaspoux C, Boudou P, Fiet J, Jouanique C, Hardy N, et al. Effects of minoxidil 2% vs. cyproterone acetate treatment on female androgenetic alopecia: a controlled, 12-month randomized trial. *Br J Dermatol* 2002; 146:992–9.
40. Carmina E, Lobo RA. Treatment of hyperandrogenic alopecia in women. *Fertil Steril* 2003; 79:91–5.
41. Lause M, Kamboj A, Fernandez Faith E. Dermatologic manifestations of endocrine disorders. *Transl Pediatr* 2017; 6:300–12.
42. Harrison S, Sinclair R. Telogen effluvium. *Clin Exp Dermatol* 2002; 27:389–95.
43. Malkud S. Telogen Effluvium: A Review. *J Clin Diagnostic Res* 2015. doi: 10.7860/JCDR/2015/15219.6492.
44. Milgraum SS, Mitchell AJ, Bacon GE, Rasmussen JE. Alopecia areata, endocrine function, and autoantibodies in patients 16 years of age or younger. *J Am Acad Dermatol* 1987; 17:57–61.
45. Baars MP, Greebe RJ, Pop VJM. High prevalence of thyroid peroxidase antibodies in patients with alopecia areata. *J Eur Acad Dermatol Venereol* 2013; 27:e137-9.
46. Patel D, Li P, Bauer AJ, Castelo-Soccio L. Screening Guidelines for Thyroid Function in Children With Alopecia Areata. *JAMA Dermatology* 2017; 153:1307.
47. Messenger AG, McKillop J, Farrant P, McDonagh AJ, Sladden M. British Association of Dermatologists' guidelines for the management of alopecia areata 2012. *Br J Dermatol* 2012; 166:916–26.
48. Bergman R, Schein-Goldshmid R, Hochberg Z, Ben-Izhak O, Sprecher E. The alopecias associated with vitamin D-dependent rickets type IIA and with hairless gene mutations: a comparative clinical, histologic, and immunohistochemical study. *Arch Dermatol* 2005; 141:343–51.
49. Wang J, Malloy PJ, Feldman D. Interactions of the Vitamin D Receptor with the Corepressor Hairless. *J Biol Chem* 2007; 282:25231–9.