

Using tuberculin syringe for withdrawing fibrin-plug in platelet-rich fibrin (PRF) therapy

Problem

Platelet-rich fibrin (PRF) therapy is a useful treatment option for a variety of non-healing ulcers. PRF secretes a number of growth factors such as platelet-derived growth factor, transforming growth factor beta 1, vascular endothelial growth factor and insulin-like growth factors, as well as cytokines and matrix glycoproteins such as thrombospondin 1, fibronectin and vitronectin.¹ One of the logistic challenges encountered during the procedure is removing the fibrin plug from the test tube. Often, it is impossible to fit commonly available non-toothed dissecting forceps into the tube; hence small-sized forceps are utilised to remove the plug. Even with the small forceps, it is difficult to grip the fibrin plug as it slides quickly and falls back into the tube, making the process tedious.

Solution

To address this issue, we propose extracting the fibrin plug from the tube with a one-ml tuberculin syringe. Blood is collected in a sterile test tube and spun for 10 minutes in a centrifuge at 3000 revolutions per minute (RPM). When platelet-rich fibrin is ready, a one-ml tuberculin syringe without a needle is introduced into the test tube, and once in contact with the fibrin plug, suction is applied on the syringe and it is withdrawn from the tube and placed over the wound [Figure 1]. Because a suction mechanism with a syringe is used, the entire platelet-rich fibrin plug comes out quickly and without deformation [Figure 2 and Video 1]. This procedure can simplify and expedite the entire process.

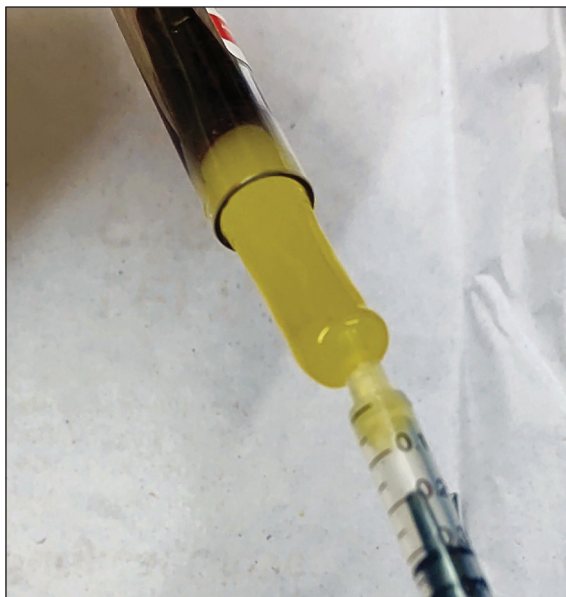

Figure 1: Tuberculin syringe used to pull out the fibrin plug from the test tube.

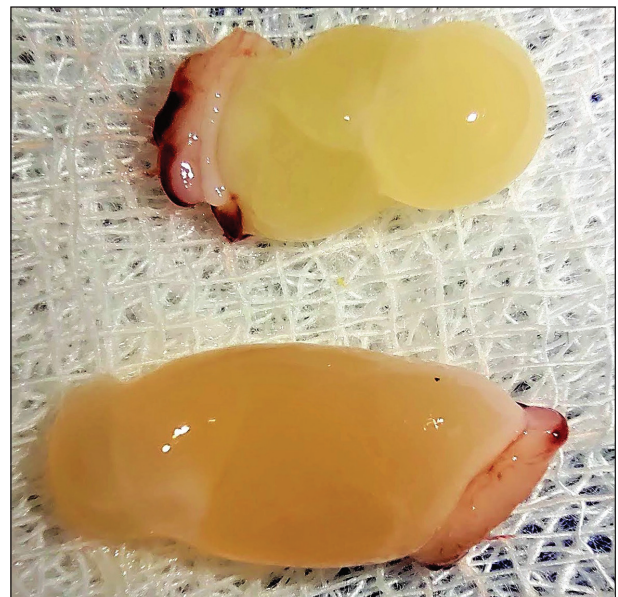


Figure 2: Platelet-rich fibrin plug.

How to cite this article: Vendhan S, Neema S, Vasudevan B, Dakshinamurthy S. Using tuberculin syringe for withdrawing fibrin-plug in platelet-rich fibrin (PRF) therapy. *Indian J Dermatol Venereol Leprol.* 2024;90:692-3. doi: 10.25259/IJDVL_1115_2023

Received: October, 2023 **Accepted:** December, 2023 **Epub Ahead of Print:** April, 2024 **Published:** August, 2024

DOI: 10.25259/IJDVL_1115_2023 **PMID:** 38841976 **Video available on:** https://doi.org/10.25259/IJDVL_1115_2023

This is an open-access article distributed under the terms of the Creative Commons Attribution-Non Commercial-Share Alike 4.0 License, which allows others to remix, tweak, and build upon the work non-commercially, as long as the author is credited and the new creations are licensed under the identical terms.

Declaration of patient consent: Patient consent not required as there are no patients in this study.

Financial support and sponsorship: Nil.

Conflicts of interest: There are no conflicts of interest.

Use of artificial intelligence (AI)-assisted technology for manuscript preparation: The authors confirm that there was no use of artificial intelligence (AI)-assisted technology for assisting in the writing or editing of the manuscript and no images were manipulated using AI.

Video 1: Demonstration of platelet-rich fibrin plug withdrawal using tuberculin syringe in a lepromatous neuropathic ulcer.

***Senkadhir Vendhan, Shekhar Neema¹,
Biju Vasudevan, Senkadhirdasan Dakshinamurthy²***

Department of Dermatology, Armed Forces Medical College,
Wanowrie, Pune, Maharashtra, ¹Department of Dermatology,
Command Hospital Kolkata, West Bengal, ²Department of Community
Medicine, Mahatma Gandhi Medical College and
Research Institute, Puducherry, India

Corresponding author:

Dr. Senkadhir Vendhan,
Department of Dermatology, Armed Forces Medical College,
Wanowrie, Pune, Maharashtra, India.
vendhan100@gmail.com

Reference

1. Karimi K, Rockwell H. The benefits of platelet-rich fibrin. *Facial Plast Surg Clin North Am* 2019;27:331–40.