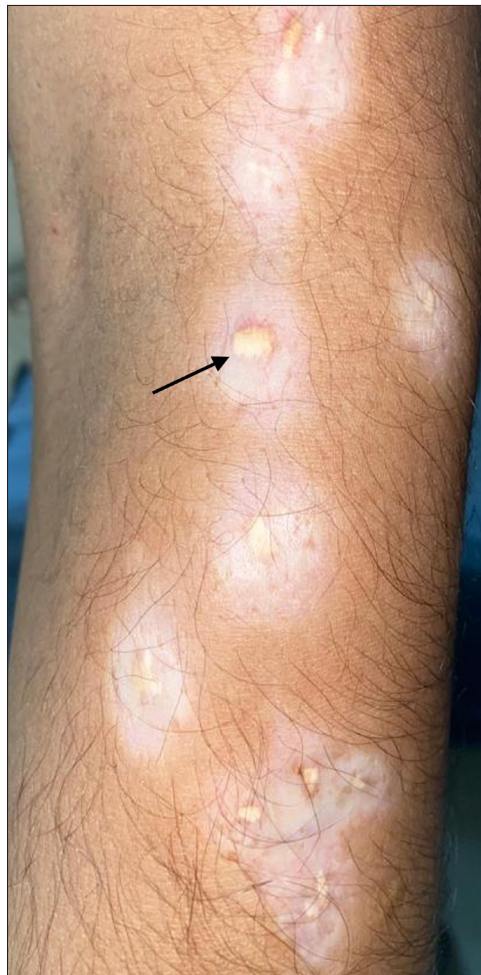

# Dermal steroid deposits due to intralesional triamcinolone



**Figure 1a:** Multiple atrophic, hypopigmented scars studded with yellowish to white papules (black arrow) in a linear distribution over right forearm

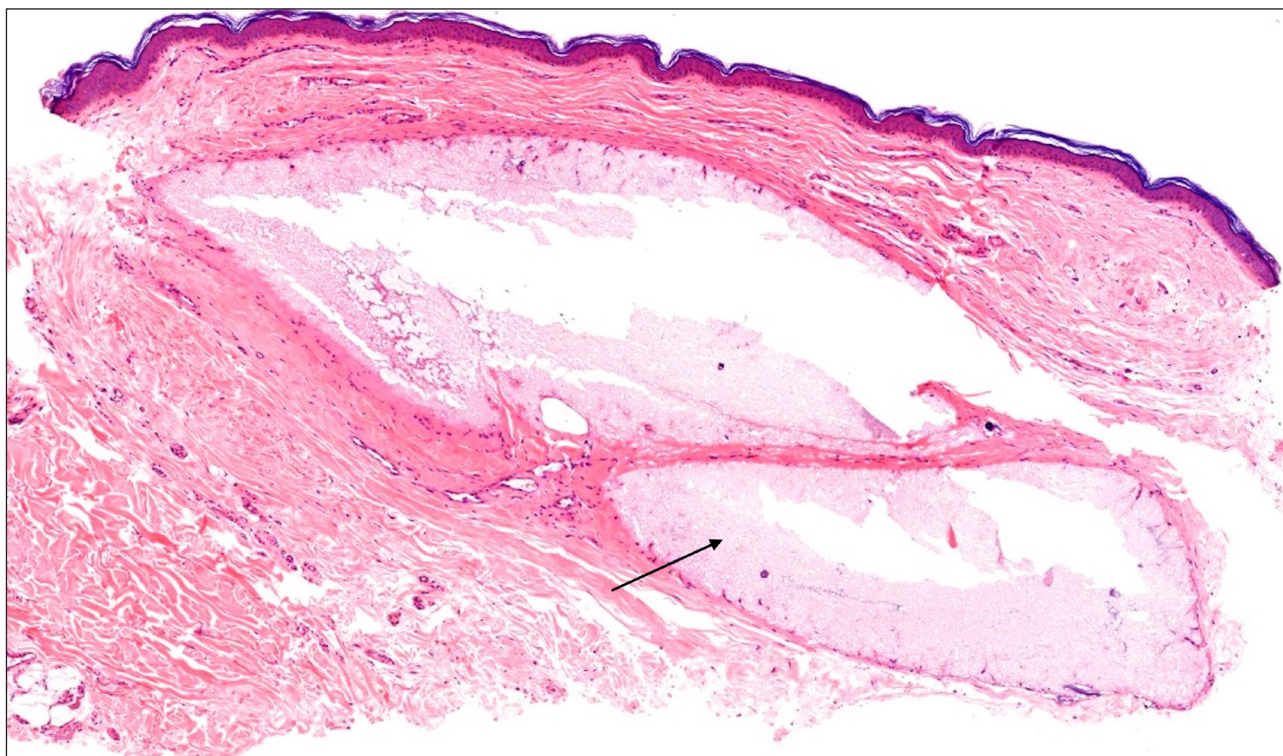
A 26-year-old male presented with multiple atrophic, hypopigmented scars studded with yellowish-to-white papules in a linear distribution over the right forearm [Figure 1a]. The lesions were initially itchy and elevated having started after a trauma 3 years ago. Most likely, those were hypertrophic scars. He was treated with multiple intralesional triamcinolone (40 mg/mL) injections over the individual scars at 1–3 month intervals, until 6 months back. The scars flattened, but hypopigmentation and papules appeared during the treatment course. Histopathology showed deposition of well-circumscribed pools of light basophilic acellular, finely granular to amorphous mucin-like material [Figure 1b] in the upper dermis. Angulated, crystal-like empty spaces with focal calcification were seen within the deposits [Figure 1c]. There was an absence of a prominent

**How to cite this article:** Kaur M, Patra S, Khera S. Dermal steroid deposits due to intralesional triamcinolone. Indian J Dermatol Venereol Leprol doi 10.25259/IJDVL\_1115\_2022.

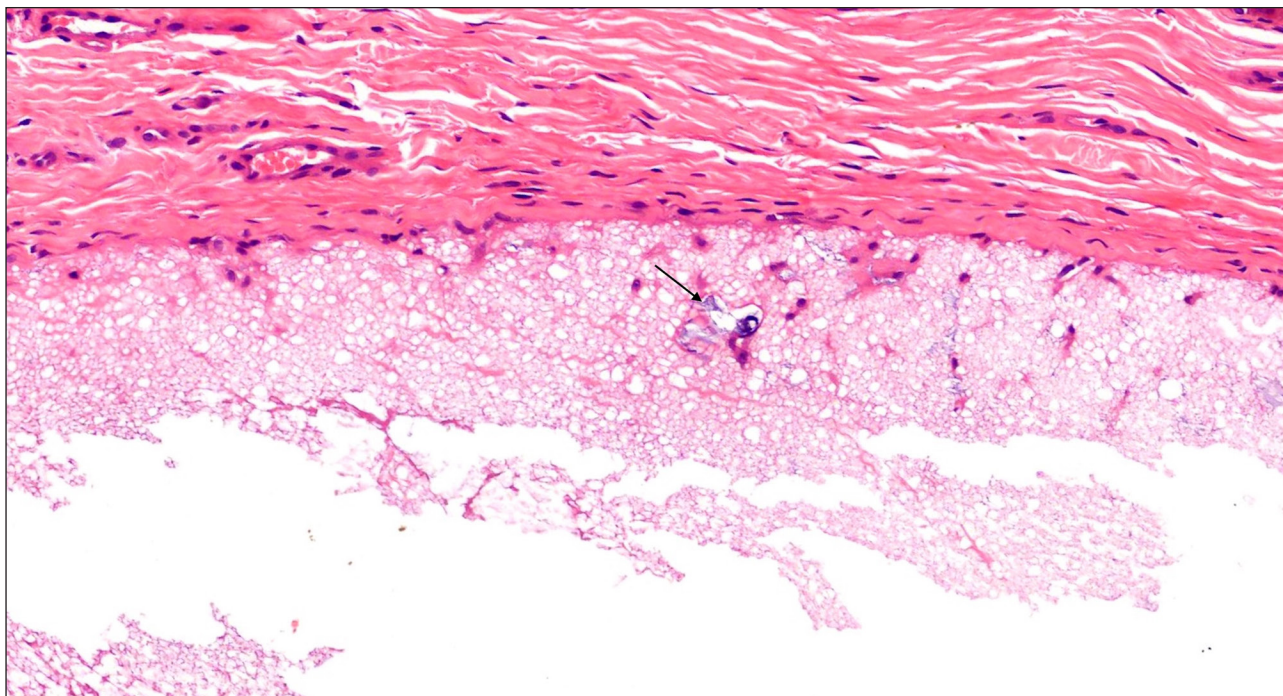
**Received:** December, 2022 **Accepted:** June, 2022 **Epub Ahead of Print:** August, 2023

**DOI:** 10.25259/IJDVL\_1115\_2022

This is an open-access article distributed under the terms of the Creative Commons Attribution-Non Commercial-Share Alike 4.0 License, which allows others to remix, tweak, and build upon the work non-commercially, as long as the author is credited and the new creations are licensed under the identical terms.



**Figure 1b:** Deposition of well-circumscribed pools of lightly basophilic acellular, finely granular to amorphous mucin-like material (black arrow) in upper dermis (H & E 100x)



**Figure 1c:** Steroid deposits with occasional foci of calcification (black arrow) (H & E 400x)

inflammatory infiltrate, barring occasional histiocytes around the deposit. The epidermis was atrophic. No birefringent crystals were found under polarised light. Periodic acid-Schiff staining did not highlight the material, and Alcian blue staining was negative for mucin. There are a few case reports of similar occurrences in the literature. The character of the deposit could vary depending on the duration of the injection. It can look like light basophilic granular material initially (similar to our case) to condensed dense bluish at later stages. Occasionally, there could be foci of calcification in older lesions.

**Declaration of patient consent**

The authors certify that they have obtained all appropriate patient consent.

**Financial support and sponsorship**

Nil.

**Conflict of interest**

There are no conflict of interest.

***Maninder Kaur, Suman Patra,  
Sudeep Khara***

Department of Dermatology, Venereology and Leprology, All India Institute of Medical Sciences (AIIMS), Jodhpur,  
Rajasthan, India

**Corresponding author:**

Dr. Suman Patra,  
Department of Dermatology, Venereology and Leprology, All India Institute of Medical Sciences Jodhpur, AIIMS Jodhpur, Jodhpur, Rajasthan, India.  
patrohere@gmail.com