

Looking for a grey needle in a ‘hair’ stack! Using a Wood’s lamp for evaluating canities

Problem

Young patients who present with early onset greying of hair require a proper evaluation to assess the extent and number of grey hair. This is often difficult if the grey hair are few in number, in patients with darker skin types and a lighter shade of hair colour (brown/brown-black) or when hair colour has been used.

Solution

The Wood’s lamp is a handy device, widely used in dermatology practice, to aid in the diagnosis of pigmentary disorders and certain fungal infections. The principle of its use in pigmentary disorders

is that melanin absorbs the ultraviolet spectrum emitted by Wood’s lamp, and thereby reduces the intensity of the fluorescence.¹

We have observed that the same principle can be applied to hair devoid of melanin. Under Wood’s lamp, grey hair (partial, complete and even coloured) stand out compared to normally pigmented hair [Figures 1a and 1b]. This phenomenon can be used in the evaluation of conditions like premature canities and also possibly to assess the regrowth in alopecia areata (where the new hair tend to be lighter in colour). The main limitation is that this does not work well



Figure 1a: Normal scalp image—grey hair not visualised clearly



Figure 1b: Demonstration of clearer visualisation of grey hair under Wood’s lamp (same patient as in Figure 1a)

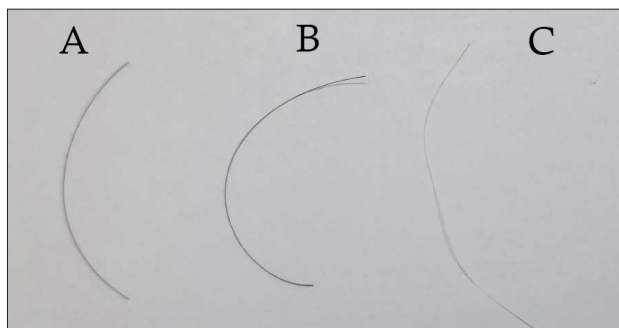


Figure 2: Normal light visualisation in three sets of hair: (A) normally pigmented hair (brown), (B) coloured (dyed) hair (black hair colour), (C) grey hair

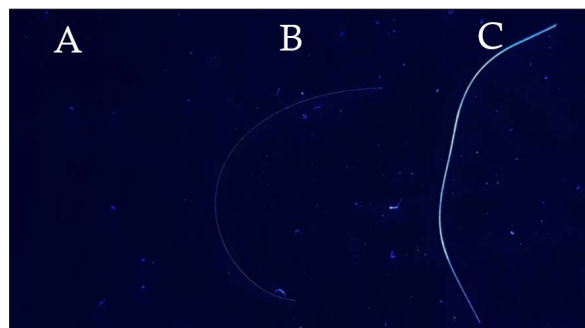


Figure 3: Wood’s lamp visualisation in the same three sets of hair as in Figure 2: (A) normally pigmented hair (brown), (B) coloured (dyed) hair (black hair colour), (C) grey hair

How to cite this article: Kaliyadan F, Jayasree P, Ashique KT. Looking for a grey needle in a ‘hair’ stack! Using a Wood’s lamp for evaluating canities. Indian J Dermatol Venereol Leprol doi: 10.25259/IJDVL_358_2022

Received: April, 2022 Accepted: July, 2022 Epub Ahead of Print: September, 2022 Published: ***

DOI: 10.25259/IJDVL_358_2022 PMID: ***

This is an open-access article distributed under the terms of the Creative Commons Attribution-Non Commercial-Share Alike 4.0 License, which allows others to remix, transform, and build upon the work non-commercially, as long as the author is credited and the new creations are licensed under the identical terms.

in people with blonde hair. An additional benefit is that when documenting grey hair, the images are clearer than natural light photography because the reflections from the hair surface often make it difficult to distinguish true grey hair [Figures 2 and 3].

Declaration of patient consent

The authors certify that they have obtained all appropriate patient consent.

Financial support and sponsorship

Nil.

Conflicts of interest

There are no conflicts of interest.

**Feroze Kaliyadan, Puravoor Jayasree¹,
Karalikkattil T. Ashique²**

Department of Dermatology, Sree Narayana Institute of Medical Sciences, Chalakka, Ernakulam, ¹Department of Dermatology, Medical Trust Hospital, Cochin, ²Amanza Skin Clinic (Amanza Health Care), Perinthlamanna, Kerala, India.

Corresponding author:

Prof. Feroze Kaliyadan,
Department of Dermatology, Sree Narayana Institute of Medical Sciences, Chalakka, Ernakulam, Kerala, India.
ferozkal@gmail.com

Reference

1. Klatte JL, van der Beek N, Kemperman PM. 100 years of Wood's lamp revised. *J Eur Acad Dermatol Venereol* 2015;29:842–7.