

# Localised urticarial eruption overlying thrombophlebitis

Sir,

Chronic urticaria is classified into spontaneous and inducible forms. Spontaneous urticaria occurs largely in a generalised distribution, whereas inducible urticaria may be localised as per the responsible trigger. The pathophysiology of urticaria is centered around the release of histamine by mast cell degranulation, which in turn is associated with a multitude of immunologic and non-immunologic triggers. The activation of the coagulation system has also been proposed as an alternate mechanism in the pathophysiology of chronic urticaria.<sup>1</sup> We describe an interesting case of chronic urticaria localised to the site of superficial thrombophlebitis, strengthening the above role in this condition.

A 44-year-old woman presented to our outpatient department with complaints of daily episodes of itchy urticarial wheals limited to the flexural aspect of the right upper limb for the last nine months [Figure 1a and b]. The wheals resolved within an hour of intake of tablet levocetirizine 5 mg without any residual pigmentation. There were no urticarial wheals at other sites concurrently or in the past. There was no history of angioedema, topical applications, localised pressure, cold, heat or sun exposure or contact with water. Dermographism could not be elicited.

Two months prior to the onset of urticaria, there was a history of spontaneous development of a linear, tender and erythematous plaque over the proximal flexor aspect of the right forearm. Doppler ultrasonography revealed a hyperechoic thrombus in the underlying basilic vein, suggestive of superficial thrombophlebitis [Figure 2]. There was no history of recent intravenous cannulation, injury, surgery or prolonged immobility and no known hypercoagulability or other comorbidities. She was not on oral contraceptive pills or any other drugs. Obstetric history was significant for two consecutive embryonic losses at less than 10 weeks of gestation. Antiphospholipid antibodies revealed a positive  $\beta$ 2-glycoprotein IgM antibody on one occasion, but negative when repeated at 12 weeks; while lupus anti-coagulant and anti-cardiolipin antibodies were negative. Thus, the modified Sapporo criteria for antiphospholipid antibody syndrome were not fulfilled in this case. She was treated with warfarin 6 mg with aspirin 75 mg daily, which led to the resolution

of thrombophlebitis on doppler ultrasonography within one week. However, two months later, she began to develop urticarial wheals limited to the approximate distribution of the basilic vein, which have continued for the past nine months.

Chronic urticaria has been shown to have multi-faceted pathophysiology with mast cell degranulation being the central event in the pathogenesis. Among the immunological triggers, anti-IgE and anti-FcRI autoantibodies and complement C5a are known to be important. However, only 50% of the patients have found to be positive for histamine-releasing autoantibodies (anti-IgE IgG) on enzyme immunoassay.<sup>2</sup> Fagiolo *et al.* showed that serum from patients containing anti-FcRI autoantibodies lost the ability to release histamine from basophils *in vitro*, yet retained the ability to induce a wheal and flare reaction upon autologous serum injection even being heat-decomplemented/IgG depleted. Hence, there could be other non-immunoglobulin serum reactants that could lead to wheal and flare reactions in patients with chronic urticaria.<sup>3</sup>

It has been postulated that activation of the extrinsic coagulation pathway is one of the triggers for mast cell degranulation. Chronic urticaria patients show raised levels of prothrombin fragments 1+2 (PF1+2, a by-product of the conversion of prothrombin to thrombin), factor VIIa, fibrin degradation products and d-dimer, with their level having a positive correlation with urticaria severity.<sup>4</sup> Thrombin has been found to facilitate mast cell adhesion to fibronectin and mast cell degranulation. It can also increase vascular permeability and hence can act as a trigger for urticaria.<sup>5</sup> Thrombin injection for the treatment of pseudoaneurysm has been reported to induce a prolonged urticarial reaction<sup>6</sup> and is also generated during attacks of hereditary angioedema.

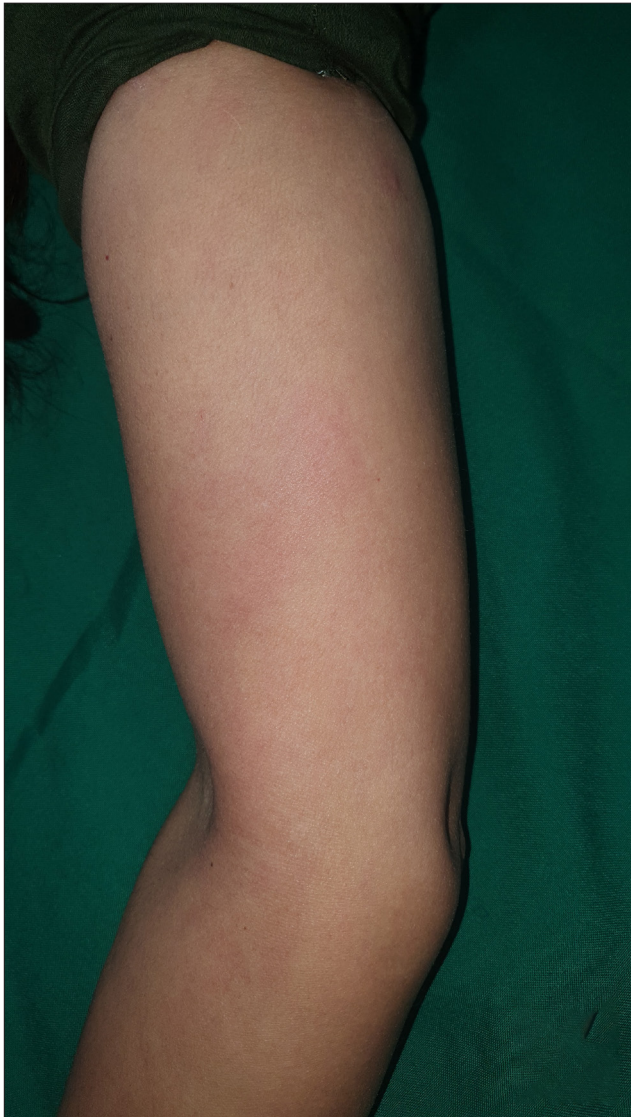The induction of tissue factors involved in the extrinsic coagulation pathway has also been associated with mast cell degranulation.<sup>7</sup> Cugno *et al.* found eosinophils to be the main source of tissue factors, which are also the main inflammatory cells in urticaria.<sup>8</sup> Tissue factor, along with factor VIIa, leads to activation of factor IIa and factor Xa, which, in turn, increases the vascular permeability via protease-activated receptor-1 and cause mast cell

**How to cite this article:** Khan I, Sharma A, Khandpur S. Localised urticarial eruption overlying thrombophlebitis. *Indian J Dermatol Venereol Leprol* 2023;89:114-116.

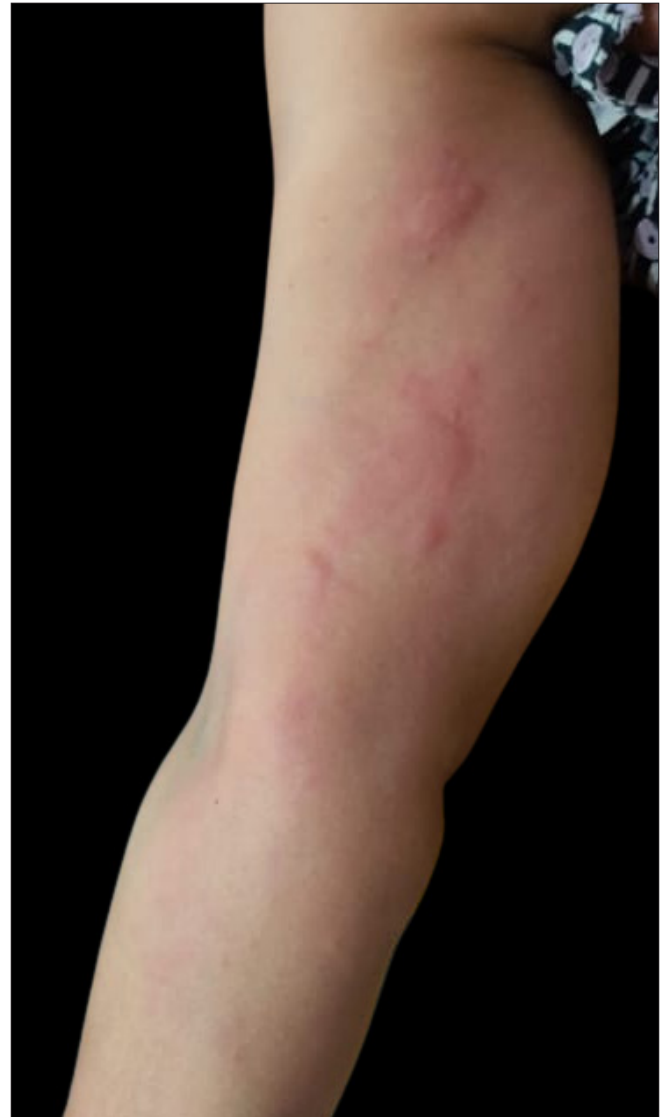Received: April, 2022 Accepted: August, 2022 EPub Ahead of Print: October, 2022 Published: January, 2023

DOI: 10.25259/IJDVL\_341\_2022 PMID: 36331831

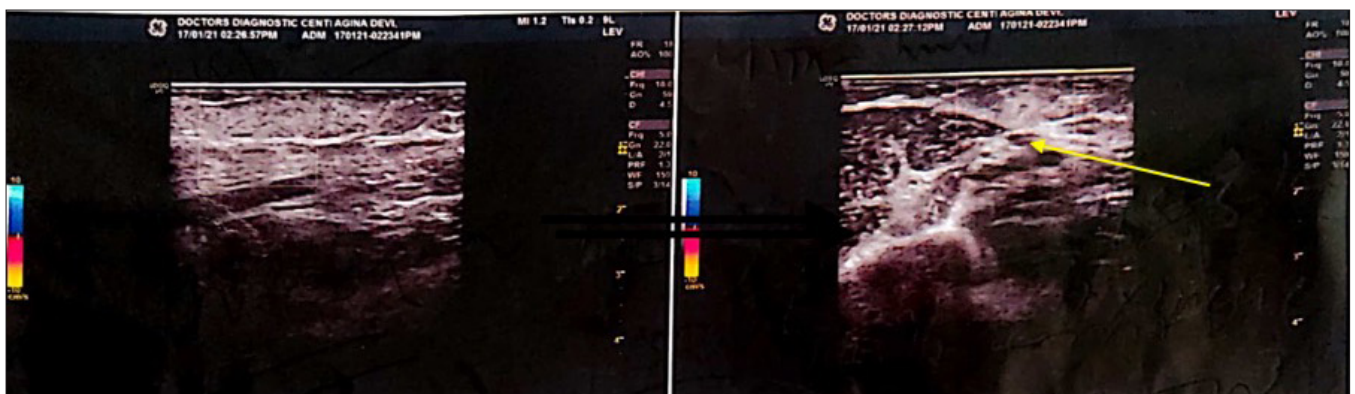
This is an open-access article distributed under the terms of the Creative Commons Attribution-Non Commercial-Share Alike 4.0 License, which allows others to remix, transform, and build upon the work non-commercially, as long as the author is credited and the new creations are licensed under the identical terms.



**Figure 1a:** Subtle urticarial wheal seen over the medial aspect of the right upper limb at presentation



**Figure 1b:** Photograph shared by the patient, showing frank urticarial wheals over the same site



**Figure 2:** Colour Doppler showing hyperechoic thrombus (yellow arrow) in a subcutaneous vessel on right upper arm and forearm without any colour flow

degranulation by activation of the C5 complement.<sup>9</sup> There have been multiple reports and trials of successful use of heparin, warfarin and tranexamic acid in patients with chronic urticaria refractory to conventional treatment. A combination of low molecular weight heparin and tranexamic acid was successfully used by Asero *et al.* in patients with raised d-dimer levels, who also found that raised d-dimer levels correlated with non-responsiveness to anti-histamines.<sup>10</sup>

Our case demonstrates an interesting direct clinical association of thrombosis with localised urticaria; strengthening the existing laboratory and circumstantial evidence correlating urticaria and the coagulation pathway.

#### Declaration of patient consent

The authors certify that they have obtained all appropriate patient consent.

#### Financial support and sponsorship

Nil.

#### Conflict of interest

There are no conflicts of interest.

***Iftexhar Khan, Ananya Sharma,  
Sujay Khandpur***

Department of Dermatology & Venereology,  
All India Institute of Medical Sciences,  
New Delhi, India.

#### Corresponding author:

Dr. Sujay Khandpur,  
Department of Dermatology and Venereology, All India Institute of  
Medical Sciences, New Delhi, India.  
sujay\_khandpur@yahoo.com

#### References

1. Cugno M, Asero R, Tedeschi A, Lazzari R, Marzano AV. Inflammation and coagulation in urticaria and angioedema. *Curr Vasc Pharmacol* 2012;10:653–8.
2. Gruber BL, Baeza ML, Marchese MJ, Agnello V, Kaplan AP. Prevalence and functional role of anti-IgE autoantibodies in urticarial syndromes. *J Invest Dermatol* 1988;90:213–7.
3. Fagiolo U, Kricek F, Ruf C, Peserico A, Amadori A, Cancian M. Effects of complement inactivation and IgG depletion on skin reactivity to autologous serum in chronic idiopathic urticaria. *J Allergy Clin Immunol* 2000;106:567–72.
4. Takahagi S, Mihara S, Iwamoto K, Morioka S, Okabe T, Kameyoshi Y, *et al.* Coagulation/fibrinolysis and inflammation markers are associated with disease activity in patients with chronic urticaria. *Allergy* 2010;65:649–56.
5. Vliagoftis H. Thrombin induces mast cell adhesion to fibronectin: Evidence for involvement of protease-activated receptor-1. *J Immunol* 2002;169:4551–8.
6. Sheldon PJ, Oglevie SB, Kaplan LA. Prolonged generalized urticarial reaction after percutaneous thrombin injection for treatment of a femoral artery pseudoaneurysm. *J Vasc Interv Radiol* 2000;11:759–61.
7. Asero R, Tedeschi A, Coppola R, Griffini S, Paparella P, Riboldi P, *et al.* Activation of the tissue pathway of blood coagulation in patients with chronic urticaria. *J Allergy Clin Immunol* 2007;119:705–10.
8. Cugno M, Marzano AV, Tedeschi A, Fanoni D, Venegoni L, Asero R. Expression of tissue factor by eosinophils in patients with chronic urticaria. *Int Arch Allergy Immunol* 2009;148:170–4.
9. Yanase Y, Takahagi S, Ozawa K, Hide M. The role of coagulation and complement factors for mast cell activation in the pathogenesis of chronic spontaneous urticaria. *Cells* 2021;10:
10. Asero R, Tedeschi A, Cugno M. Heparin and tranexamic Acid therapy may be effective in treatment-resistant chronic urticaria with elevated d-dimer: A pilot study. *Int Arch Allergy Immunol* 2010;152:384–9.

## Novel features in dermoscopy of lipid proteinosis

Sir,

Lipoid proteinosis is a rare progressive autosomal recessive disorder with infiltration of hyaline material in the skin, oral cavity, larynx and internal organs. Classically, the disease presents in early childhood with the initial manifestation being hoarseness of voice, however, late onset of the disease has been reported.<sup>1</sup>

A 23-year-old male, born to a non-consanguineous marriage, presented with a 6-month history of generalised pruritus and varied cutaneous lesions with the initial appearance of varioliform scars on the forehead. He also developed thickened verrucous plaques over bilateral elbows and on the gluteal cleft, multiple pinpoint papules over bilateral temporoparietal scalp and string of beaded papules on upper and lower palpebral margins [Figure

**How to cite this article:** Ray A, Agrawal I, Singh BS, Kar BR. Novel features in dermoscopy of lipid proteinosis. *Indian J Dermatol Venereol Leprol* 2023;89:116-118.

**Received:** October, 2021 **Accepted:** July, 2022 **Epub Ahead of Print:** October, 2022 **Published:** January, 2023

**DOI:** 10.25259/IJDVL\_1027\_2021 **PMID:** 36331838

This is an open-access article distributed under the terms of the Creative Commons Attribution-Non Commercial-Share Alike 4.0 License, which allows others to remix, transform, and build upon the work non-commercially, as long as the author is credited and the new creations are licensed under the identical terms.