

Eccrine poroma on the abdomen: A rare and atypical site

A 43-year-old man presented with a pink, fleshy, non-tender slowly growing sessile plaque on the left lumbar region of size 2.5 cm x 2 cm with a few overlying adherent scales present since 5 years [Figure 1]. Biopsy showed small uniform cuboidal cells with a central basophilic nucleus and pale eosinophilic cytoplasm arranged as micro follicles and connected by intercellular bridges. The periphery of the tumour showed multiple small tubular structures with basaloid eosinophilic structures [Figure 2]. Immunohistochemistry

BerEP4 for Basal Cell Carcinoma (BCC) was negative and p63 was positive suggestive of eccrine poroma.

Eccrine poroma is a benign adnexal tumour that originates from the intraepidermal eccrine ducts and accounts for 10% of the sweat gland tumours. Most of these tumours are located on the palms and soles but are rarely reported in unusual locations like the head and neck, upper and lower extremities and the nipple region. We report a case of eccrine poroma located in the left lumbar region.

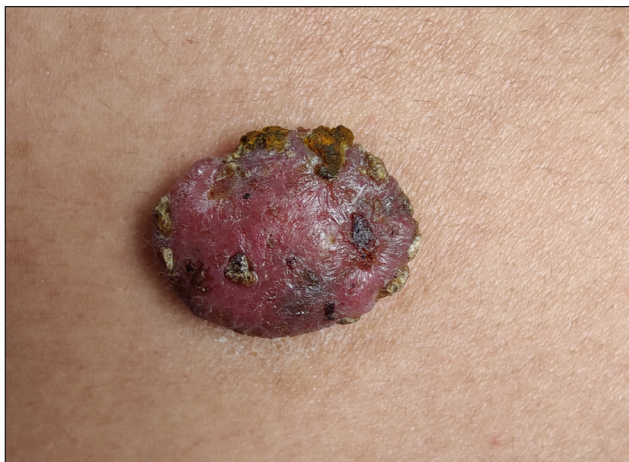


Figure 1: Sessile tumour on the abdomen with few adherent scales.

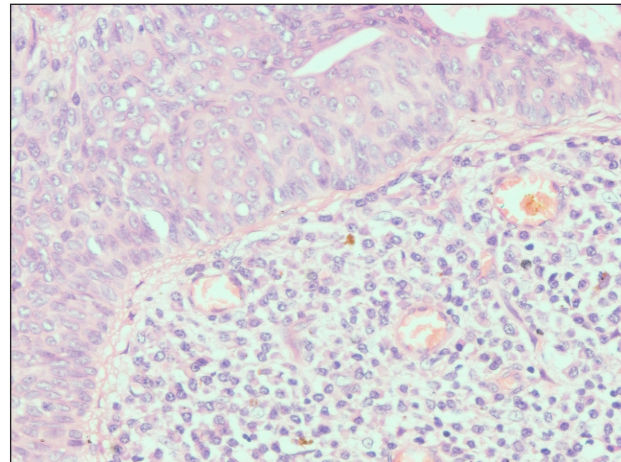


Figure 2: Small uniform cuboidal cells with a central basophilic nucleus and pale eosinophilic cytoplasm, arranged as micro follicles and differentiated from normal keratinocytes (Haematoxylin and eosin, 40x).

Declaration of patient consent

The authors certify that they have obtained all appropriate patient consent.

Financial support and sponsorship

Nil

Conflicts of interest

There are no conflicts of interest

Use of artificial intelligence (AI)-assisted technology for manuscript preparation

The authors confirm that there was no use of artificial intelligence (AI)-assisted technology for assisting in the

writing or editing of the manuscript and no images were manipulated using AI.

Shekhar Neema, Anand Mannu, Biju Vasudevan, Silky Priya

Department of Dermatology, Armed Forces Medical College, Pune, India.

Corresponding author:

Dr. Anand Mannu,
Department of Dermatology, Armed Forces Medical College,
Pune, India.
anandstanley09@gmail.com

How to cite this article: Neema S, Mannu A, Vasudevan B, Priya S. Eccrine poroma on the abdomen: A rare and atypical site. Indian J Dermatol Venereol Leprol. doi: 10.25259/IJDVL_331_2024

Received: March, 2024 **Accepted:** March, 2024 **EPub Ahead of Print:** July, 2024

DOI: 10.25259/IJDVL_331_2024

This is an open-access article distributed under the terms of the Creative Commons Attribution-Non Commercial-Share Alike 4.0 License, which allows others to remix, tweak, and build upon the work non-commercially, as long as the author is credited and the new creations are licensed under the identical terms.