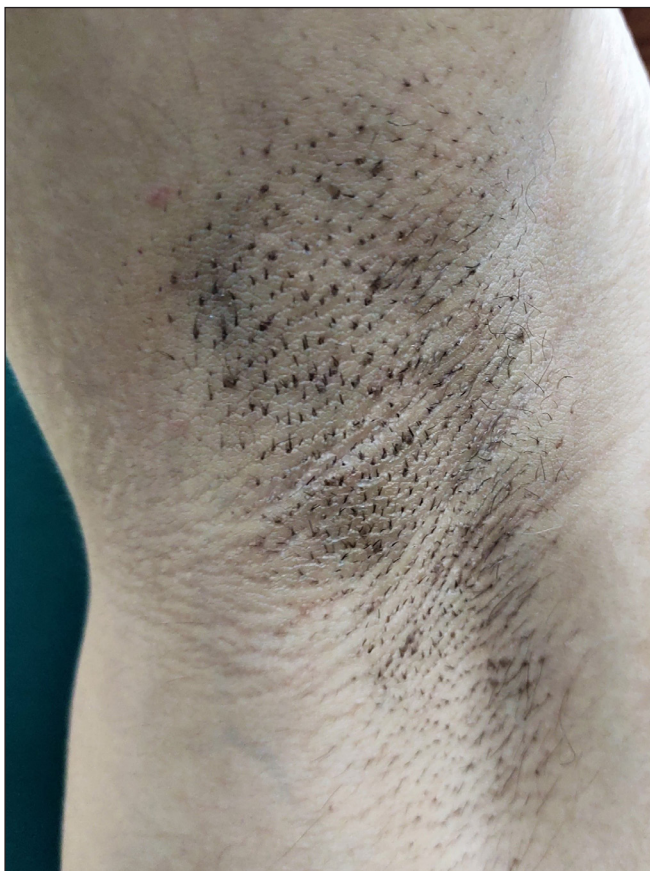


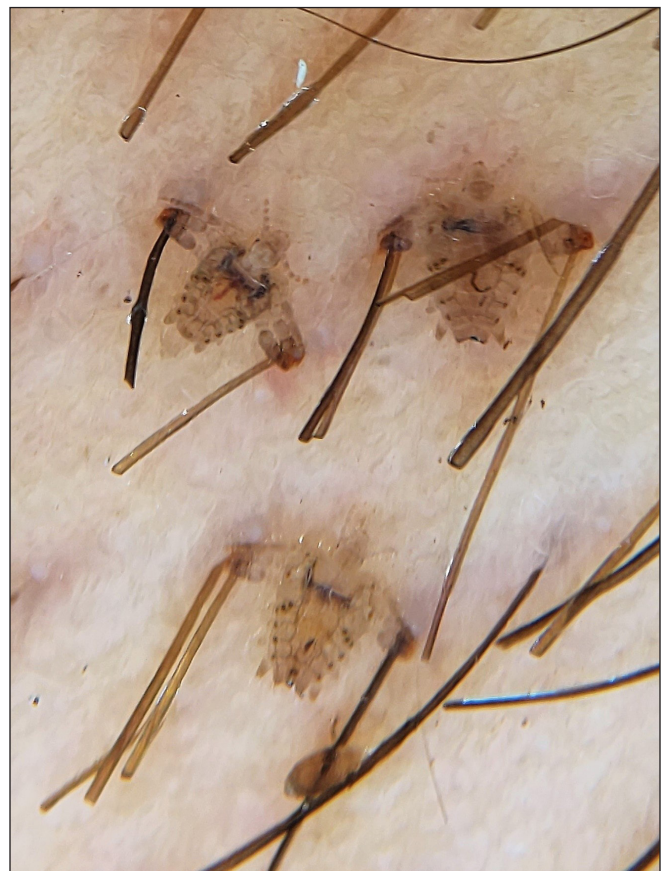## Crabs skiing in the axilla

A 21-year-old man presented with itching in the axillae for 2 months. A dermatological examination revealed follicular papules (resembling Darier's disease) and pseudofolliculitis barbae [Figure 1]. However, dermoscopy revealed the presence of numerous crab lice that were firmly attached to the hair shaft. They appeared to be skiing holding on to adjacent hair [Figure 2]. On microscopy, the louse was found to have a wide body, short antennae, crab-like appendages and narrow mouth parts confirming it to be *Pthirus pubis* [Figure 3].

The patient was treated with 1% permethrin lotion, counselled about the disease and advised to get all his contacts also treated for the same condition. At one month follow up, the patient was free from the infestation clinically and dermoscopically. Lice infestation in the axilla can mimic other conditions and a dermoscopic examination and/ or microscopy can clinch the diagnosis at the bedside thus preventing misdiagnosis or treatment delays.



**Figure 1:** Right axilla showing dark follicular papules



**Figure 2:** Dermoscopy showing three crab lice holding on to hair shafts in the axilla as if in the process of skiing (DermLite D4 dermoscope, polarising mode, magnification 10×)

**How to cite this article:** Vasudevan B, Vendhan DS, Neema S. Crabs skiing in the axilla. Indian J Dermatol Venereol Leprol doi: 10.25259/IJDVL\_166\_2023

**Received:** February, 2023 **Accepted:** March, 2023 **Epub Ahead of Print:** May, 2023

**DOI:** 10.25259/IJDVL\_166\_2023

This is an open-access article distributed under the terms of the Creative Commons Attribution-Non Commercial-Share Alike 4.0 License, which allows others to remix, tweak, and build upon the work non-commercially, as long as the author is credited and the new creations are licensed under the identical terms.



**Figure 3:** Microscopy (10×) showing *Pthirus pubis* (crab louse) with characteristic morphological features

**Declaration of patient consent**

The authors certify that they have obtained all appropriate patient consent.

**Financial support and sponsorship**

Nil.

**Conflict of interest**

There is no conflict of interest.

***Biju Vasudevan, Senkadhir Vendhan D,  
Shekhar Neema***

Department of Dermatology, Armed Forces Medical College,  
Pune, Maharashtra, India

**Corresponding author:**

Dr. Biju Vasudevan,  
Department of Dermatology, Armed Forces Medical College,  
Pune, Maharashtra, India.  
bijuvasudevan1975@gmail.com