

Rupioid psoriasis with inverse psoriasis

A 50-year-old male presented with thick, scaly lesions over the body for 15 years. On examination, he had multiple, well-defined, hyperpigmented discrete plaques studded with thick white limpet-like scales over the trunk [Figure 1], bilateral upper and lower limbs. Bilateral axillae showed well-defined hyperpigmented to erythematous plaques with minimal scaling [Figure 2]. Pitting was seen in the finger and toenails. The Psoriasis Area and Severity Index score was 16.9. Human immunodeficiency virus serology was negative. Skin biopsy showed hyperkeratosis with confluent parakeratosis,

neutrophils within the stratum corneum, diminished granular layer, regular acanthosis and dilated vessels within the dermis. Diagnosis of rupioid psoriasis with inverse psoriasis was made based on clinico-histopathological features.

Declaration of patient consent

Patient's consent not required as patients identity is not disclosed or compromised.

Financial support and sponsorship

Nil.

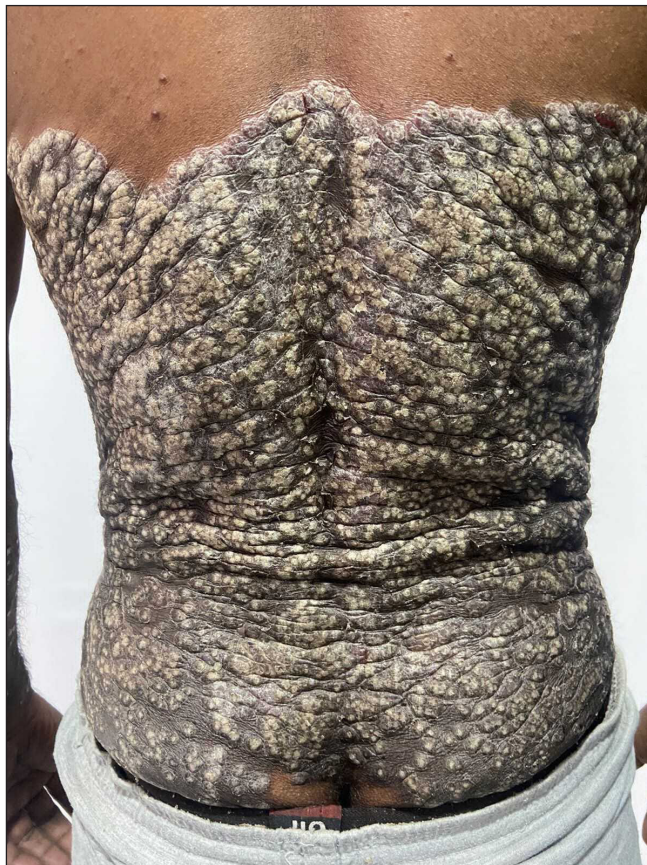


Figure 1: Well-defined, thick hyperpigmented plaque studded with limpet-like scales on the back

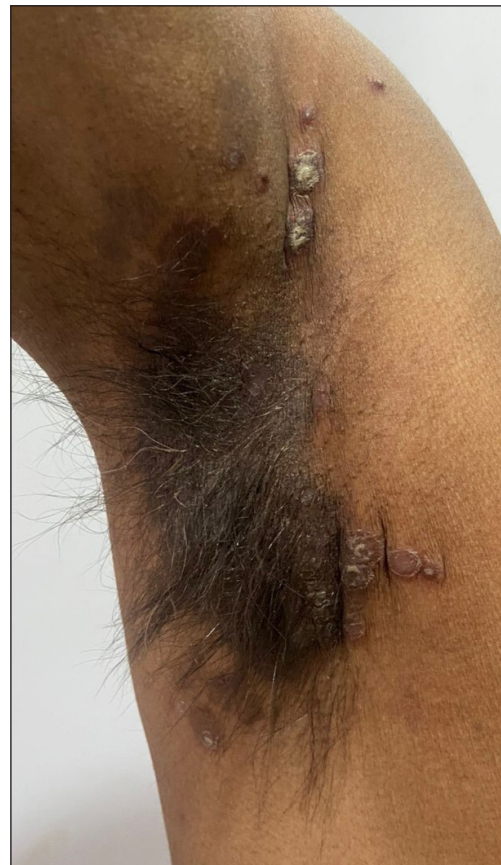

Figure 2: Well-defined hyperpigmented to erythematous plaques on axilla

How to cite this article: Sharma V, Mohanty S, Chaudhary G. Rupioid psoriasis coexisting with inverse psoriasis. Indian J Dermatol Venereol Leprol doi: 10.25259/IJDVL_1000_2022

Received: November, 2022 **Accepted:** January, 2023 **Epub Ahead of Print:** April 2023 **Published:** ***

DOI: 10.25259/IJDVL_1000_2022 **PMID:** ***

This is an open-access article distributed under the terms of the Creative Commons Attribution-Non Commercial-Share Alike 4.0 License, which allows others to remix, tweak, and build upon the work non-commercially, as long as the author is credited and the new creations are licensed under the identical terms.

Sharma, *et al.*

Conflict of interest

There are no conflicts of interest.

Vichitra Sharma, Swosti Mohanty, Garima Chaudhary

Department of Dermatology, Venereology & Leprosy,
Era's Lucknow Medical College and Hospital,
Lucknow, Uttar Pradesh, India

Rupioid psoriasis coexisting with inverse psoriasis

Corresponding author:

Dr. Vichitra Sharma,
Department of Dermatology, Venereology & Leprosy,
Era's Lucknow Medical College and Hospital,
Lucknow, Uttar Pradesh, India.
vichitrasharma26@gmail.com