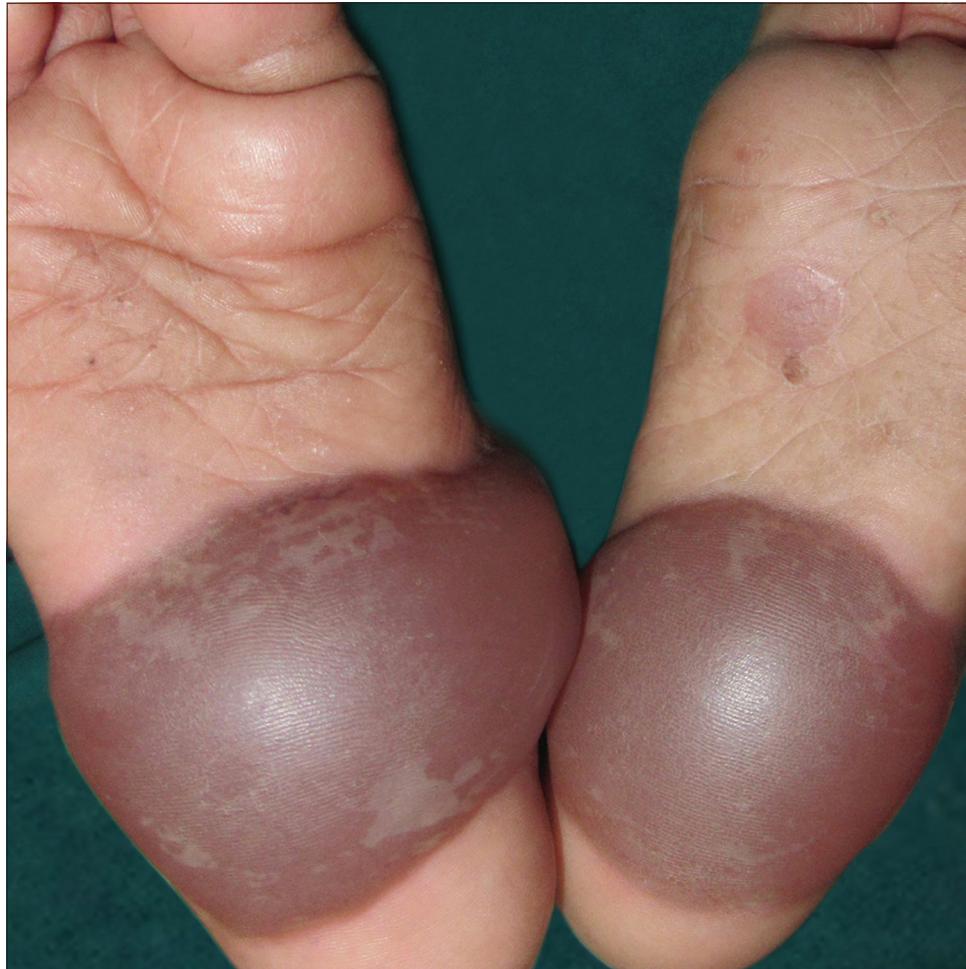


## Bullous impetigo mimicking epidermolysis bullosa



**Figure 1:** Hemorrhagic bullae on soles

A 2-year-old boy was brought with 4 days history of 2 fluid-filled lesions on soles. It was associated with minimal itching and there were no constitutional symptoms. Cutaneous examination revealed hemorrhagic bullae of approximately 4×5 cm in size on soles [Figure 1]. One healing erosion was present on the left sole. Other cutaneous, mucosal, teeth and nail examinations were

**How to cite this article:** Dash S, Palit A, Behera B. Bullous impetigo mimicking epidermolysis bullosa. *Indian J Dermatol Venereol Leprol* 2022;851-2.

**Received:** October, 2019 **Accepted:** March 2020 **Epub Ahead of Print:** February, 2021 **Published:** November, 2022

**DOI:** 10.25259/IJDVL\_871\_19 **PMID:** 33666050

This is an open-access article distributed under the terms of the Creative Commons Attribution-Non Commercial-Share Alike 4.0 License, which allows others to remix, tweak, and build upon the work non-commercially, as long as the author is credited and the new creations are licensed under the identical terms.

within normal limits. Differential diagnosis of bullous impetigo and epidermolysis bullosa was considered. The aspirated fluid was sent for bacterial culture sensitivity and oral amoxicillin with clavulanic acid 375 mg twice daily was started empirically. Aspirated fluid had grown methicillin-resistant *Staphylococcus aureus*. A final diagnosis of bullous impetigo was made. The lesions subsided completely after 7 days of treatment.

**Declaration of patient consent**

The authors certify that they have obtained all appropriate patient consent.

**Financial support and sponsorship**

Nil.

**Conflicts of interest**

There are no conflicts of interest.

***Siddhartha Dash, Aparna Palit, Biswanath Behera***

Department of Dermatology, All India Institute of Medical Sciences, Bhubaneswar, Odisha, India.

**Corresponding author:**

Dr. Biswanath Behera,

Department of Dermatology, All India Institute of Medical Sciences, Bhubaneswar - 751 019, Odisha, India.

biswanathbehera61@gmail.com